

The effect of helicobacter pylori eradication on atrophic gastritis and intestinal metaplasia : a retrospective single center research

N. Suna¹, D. Etik¹, S. Öcal¹, C. Gündüz², A. Açıkgöz², İ. Bildik², A. Gürsoy², İ. Kaşgöz², H. Tüleylioğlu², A. Boyacıoğlu¹

(1) Department of Gastroenterology, Faculty of Medicine, Başkent University, Ankara, Turkey ; (2) Department of Internal Medicine, Faculty of Medicine, Başkent University, Ankara, Turkey.

Abstract

Background and study aims : Gastric cancer (GC) is one of the major causes of cancer-related deaths worldwide. *Helicobacter pylori* (Hp) plays an important role in gastric carcinogenesis by inducing precancerous changes such as atrophic gastritis (AG) and intestinal metaplasia (IM).

In our study, we aim to compare the grade of AG and IM before and after Hp eradication in patients who underwent esophagogastroduodenoscopy (EGD) in our center.

Patients and methods : The data of 40.060 patients who underwent EGD for various reasons in our Endoscopy Unit between June 2011 and November 2017 were retrospectively evaluated. The grade of AG and IM before and after Hp eradication of patients meeting the study criteria were compared with each other. In addition, these findings were compared using OLGA and OLGIM staging systems.

Results : A total of 175 patients, 89 (50.9%) women and 86 (49.1%) men, were included in the study. The mean age was 55±12 years. The mean time between two EGD examinations was 38±14 months. Significant improvement was observed in the grade of AG on corpus and antrum after Hp eradication (P=0.000, P=0.008). In the corpus and antrum, the grade of IM was regressed but this was not significant (P=0.80 and P=0.370 respectively). There was a decrease in OLGA stages after Hp eradication (P=0.000). There was also a reduction in the OLGIM stages, but this was not significant (P=0.341).

Conclusion : Our study demonstrates that Hp eradication may reduce the risk of developing GC by providing an improvement in AG and IM which are precancerous changes in GC. (*Acta gastroenterol. belg.*, 2020, 83, 381-384).

Introduction

Gastric cancer (GC) is one of the major causes of cancer-related deaths all over the world despite the decline in developed countries (1,2). Although the prevalence of *Helicobacter pylori* (Hp) varies widely between regions, it affects more than half of the world population (3). Hp plays an important role in gastric carcinogenesis. It causes predisposition to GC by inducing precancerous changes such as atrophic gastritis (AG) and intestinal metaplasia (IM) (4,5). The risk of developing GC is reported to be 3-6 times higher in patients with Hp infection than those without Hp infection (6,7).

Hp eradication has been reported to improve gastric inflammation, gastric mucosal damage, gastric acid secretion disorder and Hp-induced DNA damage (8). More importantly, it has been reported in some studies that AG and IM, which are considered as

precancerous lesions for GC, have been improved by Hp eradication (9-11). However, there are also studies reporting that Hp eradication does not cause any change in precancerous lesions, especially in IM (12-14). In our study, we aim to compare the grade of AG and IM before and after Hp eradication in patients who underwent esophagogastroduodenoscopy (EGD) in our center. In addition to the previous studies, it was aimed to confirm these findings by using staging systems like OLGA (*operative link on gastritis assessment*) and OLGIM (*operative link on gastric intestinal metaplasia assessment*) (15,16).

Patients/materials and methods:

Data of 40.060 patients aged 18 years and older who underwent EGD for various reasons between June 2011 and November 2017 at our Endoscopy Unit were evaluated retrospectively. We excluded patients with history of Hp eradication (n=3.954), history of gastric surgery (n=203), history of GC (n=195), EGD only once (n=20.239), shorter interval than 2 years between two EGD sessions (n=6.574), no biopsy at EGD (n=6.659), negative for Hp at first EGD (n=1.448), no AG or IM at first EGD (n=601), rejecting Hp eradication (n=5) and intolerant Hp eradication (n=7). The final study sample consisted of 75 patients ; see for more details the flowchart in Figure 1.

The data of patients were taken from NUCLEUS Medical Information System (MONAD Software and Consulting, Ankara, Turkey) which was used in our center since 2011. Demographic characteristics, Hp eradication protocols, histopathological findings of biopsies taken in EGD were recorded for the patients who met the study criteria. In all patients undergoing EGD, sedative drugs such as propofol, ketamine and midazolam were administered by intravenous route in the presence of anesthesiologist and conscious sedation was achieved. The procedures were performed with

Correspondence to : Nuretdin Suna, MD, Faculty of Medicine, Başkent University, Mareşal Fevzi Çakmak Cd. No 45, Çankaya/Ankara, PC: 06490.
E-mail : nurettinsuna.44@hotmail.com

Submission date : 30/03/2019

Acceptance date : 24/03/2020

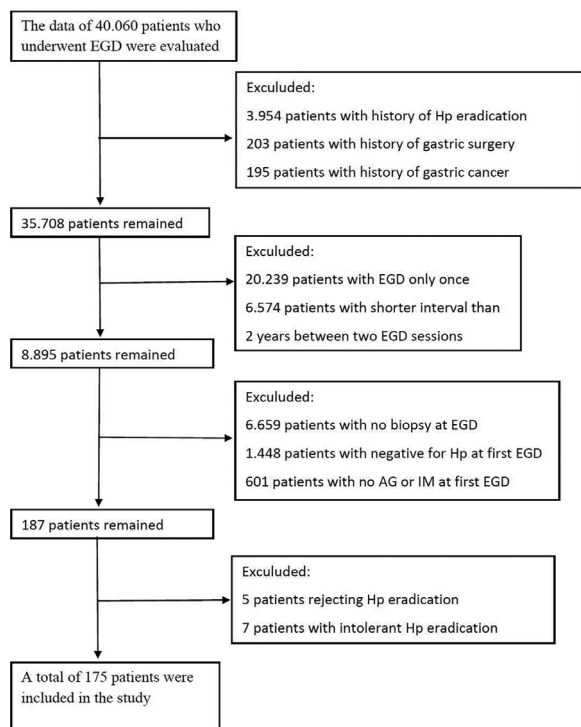


Fig 1.

standart endoscopy devices (*GIF-H260 ve GIF-Q240; Olympus, Tokyo, Japan*) in our center. According to the updated Sydney System; two biopsies from the antrum (taken from greater and lesser curvatures at a distance of 2-3 cm from the pylorus), two biopsies from the corpus (taken from greater and lesser curvatures at a distance of 8 cm from the cardia) and one biopsy from the incisura angularis were performed (17). In addition, biopsies were taken from suspicious areas detected in endoscopic imaging. Histopathologically, AG and IM were graded using updated Sydney System (17). The grade of AG and IM, which were determined before and after Hp eradication in patients, were compared by using OLGA and OLGIM staging systems (15,16).

Our study was approved by our University Medical and Health Sciences Research Council (KA 18/84). The data of our study were analyzed by our University Department of Public Health using IBM SPSS version 22.0 statistical package program. The findings of patients before and after Hp eradication were presented as number and percentage distribution. The change between the findings of pre and post eradication of Hp was evaluated by Chi-Square Analysis. $P < 0.05$ was considered statistically significant.

Results

The data of 40.060 patients who underwent EGD for various reasons between June 2011 and November 2017 at our Endoscopy Unit were evaluated retrospectively. A total of 175 patients, 89 (50.9%) of whom were female and 86 (49.1%) were male, were included in the study.

The age of the patients ranged from 19 to 80 years and the mean age was 55 ± 12 years. The mean time between the two EGDs was 38 ± 14 months. Alcohol and cigarette smoking were %12 and %25, respectively. While %45 of patients did not have an additional disease, they were most frequently found to have essential hypertension (20%), diabetes mellitus (14%) and coronary artery disease (7%). The proportion of patients with a history of gastric cancer in their first and/or second degree relatives was 13%. The rate of using proton pump inhibitors (PPI) was 42% before EGD. The most common indications of EGDs before eradication of Hp were dyspepsia (47.3%), ulcer (29.8%) and reflux (1.2%). The most common endoscopic findings in the first EGD were erythematous gastropathy (52.3%), reflux esophagitis (19.8%) and duodenitis (12.6%), respectively. The first three treatment regimens used for the eradication of Hp were amoxicillin + clarithromycin + PPI + bismuth subsitrate (32%), amoxicillin + levofloxacin + PPI + bismuth subsitrate (31%) and metronidazole + tetracycline + PPI + Bismuth subsitrate (26%), respectively.

The grade of AG in corpus and antrum before and after Hp eradication are shown in Table 1. According to this, there was a significant decrease in AG levels in both corpus and antrum after Hp eradication ($P=0.000$, $P=0.008$). Table 2 summarizes the grade of IM in corpus and antrum before and after Hp eradication. Although there was a regression in the grade of IM in corpus and antrum after Hp eradication, it was not statistically significant ($P=0.80$, $P=0.370$ respectively). Table 3 shows the grade of IM and AG according to the OLGA and OLGIM staging systems before and after Hp eradication. Significant regression of AG stages was detected after Hp eradication according to OLGA staging system ($P=0.00$). After Hp eradication, there were regression of IM stages in OLGI staging system but not statistically significant ($P=0.341$).

Discussion

GC still remains the third most common cause of cancer-related deaths. It is ranked fifth in the world cancer incidence (1,2). Primary prevention and early diagnosis by risk factor modification is important for GC

Table 1. — **The grade of AG in corpus and antrum before and after Hp eradication**

Location	Corpus				Antrum			
	Before Eradication		After Eradication		Before Eradication		After Eradication	
Grade	n	%	n	%	n	%	n	%
0	131	74.8	138	78.9	72	41.2	95	54.3
1	26	14.9	28	16	67	38.3	69	39.4
2	12	6.9	7	4	27	15.4	7	4
3	6	3.4	2	1.1	9	5.1	4	2.3
P value	0.000				0.008			

AG, Atrophic gastritis ; Hp, Helicobacter pylori.

Table 2. — The grade of IM in corpus and antrum before and after Hp eradication

Location	Corpus				Antrum			
	Before Eradication		After Eradication		Before Eradication		After Eradication	
Grade	n	%	n	%	n	%	n	%
0	66	37.7	92	52.5	24	13.7	52	29.7
1	49	28	40	22.9	70	40	56	32
2	53	30.3	33	18.9	74	42.3	59	33.7
3	7	4	10	5.7	7	4	8	4.6
P value	0.80				0.370			

IM, Intestinal metaplasia ; Hp, Helicobacter pylori.

Table 3. — The OLGA and OLGIM stages before and after Hp eradication

	OLGA				OLGIM			
	Before Eradication		After Eradication		Before Eradication		After Eradication	
Stage	n	%	n	%	n	%	n	%
0	67	38.3	87	49.7	20	11.4	49	28
1	71	40.6	76	43.4	69	39.5	54	30
2	17	9.7	4	2.3	27	15.4	33	18.9
3	15	8.6	7	4	53	30.3	30	17.1
4	5	2.8	1	0.6	6	3.4	9	5.1
P value	0.000				0.341			

Hp, Helicobacter pylori ; OLGA, Operative link on gastritis assessment ; OLGIM, Operative link on gastric intestinal metaplasia assessment.

(18). Major risk factors for GC include: Hp infection, precancerous lesions -AG and IM-, salt and salt-dried foods, smoking, alcohol, obesity, low socioeconomic status and family history for GC (19,25). Hp infection remains a major public health problem worldwide. A systematic meta-analysis has recently been reported that approximately 4.4 billion people worldwide have Hp infection in 2015 (3). In the same meta-analysis, the prevalence of Hp was reported to be the most prevalent in Africa (79.1%), Latin America and the Caribbean (63.4%) and Asia (54.7%). In contrast, Hp prevalence was reported to be the lowest in North America (37.1%) and Oceania (24.4%).

It is known that patients with Hp infection have a higher risk of developing GC than those without Hp infection (6,7). Furthermore, prophylactic eradication of Hp after endoscopic resection in early GC has been reported to reduce the risk of developing metachronous GC (26). In the presence of Hp infection, the gastric mucosa may progress to various degrees of chronic gastritis, AG and IM, which are risk factors for GC (4,5). Regression of AG and IM is known to be important in the prevention of intestinal type GC (27). Since Hp plays an important role in the development of AG and IM, Hp eradication is expected to reduce the development of intestinal type GC by providing regression in AG and IM. For these reasons, most of the studies were directed to the relationship between Hp and AG/IM. However, there

are conflicting results regarding the improvement of AG and IM with Hp infection (9-14). Although Hp plays an important role in the development AG and IM, they are not included in the absolute indication of Hp eradication today (28).

In the literature, there are studies reporting that AG and IM decreased with Hp eradication (9-11). Similar findings were obtained in our study. After Hp eradication, there were a significant improvement in AG grades in both antrum and corpus ($P=0.000$, $P=0.008$). After the eradication of Hp, the grade of IM in antrum and corpus were found to be regressed but not statistically significant ($P=0.80$, $P=0.370$). Unlike previous studies, these findings were confirmed using OLGA and OLGIM staging systems (15,16). However, in some studies, it has been reported that Hp eradication does not cause any change in IM and AG, more in IM (12-14).

Several reasons have been suggested to explain why AG and IM respond to Hp eradication with different rate or degree of improvement. One of the reasons for this is the histological progression of AG to IM. AG has been reported progress to severe AG, IM and gastric cancer in 10 years or longer (29). Thus, the time required for IM recovery is expected to be longer than AG. Another reason is that different risk factors play a role in the formation of AG and IM. In the development of AG, Hp virulence genes including CagA and vacA m1 are very important, while in addition to Hp, environmental and host factors have been reported to be important in the development of IM (30,31). Finally, the occurrence of IM is associated with abnormal expression of CDX1 and CDX2, suggesting that down regulation of CDX1 and CDX2 may be required in IM recovery [32,33]. Both CDX1 and CDX2 mRNA levels were reduced by IM recovery, but CDX1 and CDX2 mRNA levels were reported to be increased by the exacerbation of IM (34).

In the recent European Pre-epithelial precancerous diseases and lesions (MAPS II) guidelines, it recommends Hp eradication as it can provide regression of atrophic gastritis. Hp eradication does not considerably decrease the risk of GC in patients with IM. However, Hp eradication should be offered to patients with IM due to it may result in resolving inflammation and improvement in atroph (34). Our study findings support the recommendations of MAPSII guideline.

Our study had some limitations. First, the grade of AG and IM was not compared between those who received Hp eradication and those who did not. Instead, we compared the grade of AG and IM before and after Hp eradication. Another limitation, our study is retrospective. However, the data of patients in the endoscopy unit of our center are fully recorded on the computer environment and well protected. Finally, the mean time between two endoscopy was 38 ± 14 months. This time interval was insufficient to determine the mean times required for AG and IM recovery after Hp eradication.

In conclusion, Hp eradication showed a significant improvement in the grade of AG. In the grade of IM, there was a decline, but not statistically significant. Furthermore, unlike previous studies, these findings were confirmed using OLGA and OLGIM staging systems. Thus, our study found that Hp eradication has the potential to reduce the risk of developing gastric GC by providing improvement in AG and IM, which are precancerous changes in GC.

Acknowledgments

The authors have no sources of funding for this study and have no conflicts of interest to declare.

References

1. FERRO A., PELETEIRO B., MALVEZZI M., ET AL. Worldwide trends in gastric cancer mortality (1980-2011), with predictions to 2015, and incidence by subtype. *Eur. J. Cancer*, 2014, **50** : 1330-44.
2. FERLAY J., SOERJOMATARAM I., DIKSHIT R., ET AL. Cancer incidence and mortality worldwide: sources, methods and major patterns in GLOBOCAN 2012. *Int. J. Cancer*, 2015 Mar 1, **136**(5) : E359-86.
3. HOOÏ KY., LAÏ WY., NG WK., ET AL. Global Prevalence of Helico-bacter pylori Infection : Systematic Review and Meta-Analysis. *Gastro-enterology*, 2017 Aug, **153**(2) : 420-9.
4. UEMURA N., OKAMOTO S., YAMAMOTO S., ET AL. Helicobacter pylori infection and the development of gastric cancer. *N. Engl. J. Med.*, 2001, **345** : 784-9.
5. LÍ D., BAUTISTA MC., JĀNG SF., ET AL. Risks and predictors of gastric adenocarcinoma in patients with gastric intestinal metaplasia and dysplasia : a population-based study. *Am. J. Gastroenterol.*, 2016, **111** : 1104-13.
6. HELICOBACTER AND CANCER COLLABORATIVE GROUP. Gastric cancer and Helicobacter pylori : a combined analysis of 12 case control studies nested within prospective cohorts. *Gut*, 2001 Sep, **49**(3) : 347-53.
7. PARSONNET J., FRIEDMAN GD., VANDERSTEEN DP., ET AL. Helicobacter pylori infection and the risk of gastric carcinoma. *N. Engl. J. Med.*, 1991, **325** : 1127-31.
8. MACHADO AM., FÍGUEIREDO C., TOUATI E., ET AL. Helicobacter pylori infection induces genetic instability of nuclear and mitochondrial DNA in gastric cells. *Clin. Cancer Res.*, 2009, **15** : 2995-3002.
9. HWANG YJ., KIM N., LEE HS., ET AL. Reversibility of atrophic gastritis and intestinal metaplasia after Helicobacter pylori eradication - a prospective study for up to 10 years. *Aliment. Pharmacol. Ther.*, 2018 Feb, **47**(3) : 380-90.
10. SUNG JJ., LÍN SR., CHING JY., ET AL. Atrophy and intestinal metaplasia one year after cure of H. pylori infection : a prospective, randomized study. *Gastroenterology*, 2000, **119** : 7-14.
11. KODAMA M., MURAKAMI K., OKIMOTO T., ET AL. Helicobacter pylori eradication improves gastric atrophy and intestinal metaplasia in long-term observation. *Digestion*, 2012, **85**(2) : 126-30.
12. LEE Y.C., CHEN T.H., CHIU H.M., ET AL. The benefit of mass eradication of Helicobacter pylori infection : A community-based study of gastric cancer prevention. *Gut*, 2013, **62** : 676-82.
13. LAHNER E., BORDÍ C., CATTARUZZA MS., ET AL. Long-term follow-up in atrophic body gastritis patients : atrophy and intestinal metaplasia are persistent lesions irrespective of Helicobacter pylori infection. *Aliment. Pharmacol. Ther.*, 2005, **22** : 471-81.
14. SATOH K., KÍMURA K., TAKÍMOTO T., KÍHÍRA K. A follow-up study of atrophic gastritis and intestinal metaplasia after eradication of Helicobacter pylori. *Helicobacter*, 1998 Dec, **3**(4) : 236-40.
15. RUGGE M., GENTA RM., OLGA GROUP. Staging gastritis : an international proposal. *Gastroenterology*, 2005, **129**(5) : 1807-8.
16. CAPELLE LG., DE VRÍES AC., HARINGSMA J., ET AL. The staging of gastritis with the OLGA system by using intestinal metaplasia as an accurate alternative for atrophic gastritis. *Gastrointest. Endosc.*, 2010 Jun, **71**(7) : 1150-8.
17. DIXON MF., GENTA RM., YARDLEY JH., CORREA P. Classification and grading of gastritis. The updated Sydney System. International Workshop on the Histopathology of Gastritis, Houston 1994. *Am. J. Surg. Pathol.*, 1996 Oct, **20**(10) : 1161-81.
18. LEUNG WK., SUNG JJ. Chemoprevention of gastric cancer. *Euro. J. Gastroenterol. Hepatol.*, 2006, **18** : 867-71.
19. DE VRÍES AC., VAN GRIEKEN NC., LOOMAN CW., ET AL. Gastric cancer risk in patients with premalignant gastric lesions : a nationwide cohort study in the Netherlands. *Gastroenterology*, 2008 Apr, **134**(4) : 945-52.
20. TSUGANE S. Salt, salted food intake, and risk of gastric cancer : epidemiologic evidence. *Cancer Sci.*, 2005, **96** : 1-6.
21. GONZALEZ CA., PERA G., AGUDO A., ET AL. Smoking and the risk of gastric cancer in the European Prospective Investigation Into Cancer and Nutrition (EPIC). *Int. J. Cancer*, 2003, **107** : 629-34.
22. TRAMACERE L., NEGRÍ E., PELUCCHÍ C., ET AL. A meta-analysis on alcohol drinking and gastric cancer risk. *Ann. Oncol.*, 2012, **23** : 28-36.
23. ROKKAS T., SECHOPOULOS P., PÍSTIOLAS D., MARGANTÍNIS G., KOUKOULÍ S. Helicobacter pylori infection and gastric histology in first-degree relatives of gastric cancer patients : a meta-analysis. *Eur. J. Gastroenterol. Hepatol.*, 2010, **22** : 1128-33.
24. CHEN Y., LIU L., WANG X., ET AL. Body mass index and risk of gastric cancer : a meta-analysis of a population with more than ten million from 24 prospective studies. *Cancer Epidemiol. Biomarkers Prev.*, 2013, **22** : 1395-408.
25. BARKER DJ., COGGON D., OSMOND C., WÍCKHAM C. Poor housing in childhood and high rates of stomach cancer in England and Wales. *Br. J. Cancer*, 1990, **61** : 575-8.
26. FUKASE K., KATO M., KÍKUCHÍ S., ET AL. Effect of eradication of Helicobacter pylori on incidence of metachronous gastric carcinoma after endoscopic resection of early gastric cancer : an open-label, randomised controlled trial. *Lancet*, 2008, **372** : 392-7.
27. MALIK TH., SAYAHAN MY., AL AHMED HA., HONG X. Gastric Intestinal Metaplasia : An Intermediate Precancerous Lesion in the Cascade of Gastric Carcinogenesis. *J. Coll. Physicians Surg. Pak.*, 2017 Mar, **27**(3) : 166-72.
28. Chey WD, Leontiadis GI, Howden CW, Moss SF. ACG Clinical guideline : treatment of Helicobacter pylori infection. *Am. J. Gastroenterol.*, 2017, **112** : 212-39.
29. CORREA P., HOUGHTON J. Carcinogenesis of Helicobacter pylori. *Gastroenterology*, 2007, **133** : 659-72.
30. KÍM N., PARK YS., CHO SI., ET AL. Prevalence and risk factors of atrophic gastritis and intestinal metaplasia in a Korean population without significant gastroduodenal disease. *Helicobacter*, 2008, **13** : 245-55.
31. PARK YH., KÍM N. Review of atrophic gastritis and intestinal metaplasia as a premalignant lesion of gastric cancer. *J. Cancer Prev.*, 2015, **20** : 25-40.
32. SHIN CM., KÍM N., CHANG H., KÍM JS., LEE DH., JUNG HC. Follow-up study on CDX1 and CDX2 mRNA expression in noncancerous gastric mucosae after Helicobacter pylori eradication. *Dig. Dis. Sci.*, 2016, **61** : 1051-9.
33. KANG JM., LEE BH., KÍM N., ET AL. CDX1 and CDX2 expression in intestinal metaplasia, dysplasia and gastric cancer. *J. Korean Med. Sci.*, 2011, **26** : 647-53.
34. PÍMENTEL-NUNES P., LÍBÂNÍO D., MARCOS-PÍNTO R., ET AL. Management of epithelial precancerous conditions and lesions in the stomach (MAPS II) : European Society of Gastrointestinal Endoscopy (ESGE), European Helicobacter and Microbiota Study Group (EHMSG), European Society of Pathology (ESP), and Sociedade Portuguesa de Endoscopia Digestiva (SPED) guideline update 2019. *Endoscopy*, 2019, **51**(4) : 365-388.