

## Diagnosis and screening for anal intraepithelial neoplasia in Belgium: position statement

Ph. Roelandt<sup>1,2</sup>, D. De Looze<sup>3</sup>, H. De Schepper<sup>4</sup>, V. Ledouble<sup>5</sup>, M. Surmont<sup>6</sup>, T. Cuming<sup>7</sup>

(1) Department of Gastroenterology and Hepatology, University Hospitals Leuven, Leuven, Belgium; (2) Translational Research in Gastrointestinal Diseases (TARGID), Department of Chronic Diseases, Metabolism and Ageing (CHROMETA), KU Leuven, Leuven, Belgium; (3) Department of Gastroenterology, University Hospital Ghent, Ghent, Belgium; (4) Department of Gastroenterology and Hepatology, University Hospital Antwerp, Antwerp, Belgium; (5) Department of Gastroenterology, CHR de la Citadelle, Liège, Belgium; (6) Department of Gastroenterology and Hepatology, University Hospitals Brussels, Brussels, Belgium; (7) Department of Surgery, Homerton Anal Neoplasia Service, Homerton University Hospital, London, United Kingdom.

### Abstract

Anal cancer is an uncommon malignancy, comprising only 2.5% of all gastrointestinal malignancies and similar to cervical cancer, the human papillomavirus (HPV) is responsible for the majority of anal cancers. Over the last decades there has been an up to 3-fold increased incidence seen in specific populations at risk such as persons living with HIV (PLWH), men who have sex with men (MSM), woman diagnosed with HPV-related gynaecological precancerous lesions or cancer, solid organ transplant recipients (SOTR) and patients with autoimmune diseases. Although international practice is evolving increasingly towards active screening for and treatment of anal cancer precursors in at-risk groups, currently no organised screening program is in effect in Belgium. Currently, different screening options as well as treatment modalities are available. Before commencing a nationwide organised screening program, essential decisions on screening strategies need to be made, based on both scientific as well as financial and logistical facts. (*Acta gastroenterol. belg.*, 2022, 85, 625-631).

**Keywords:** Anal intraepithelial neoplasia, HPV, anal cancer, screening.

**Abbreviations:** AIN: anal intraepithelial neoplasia; ASCUS: atypical squamous cells of unknown significance; cART: combined antiretroviral therapy; CMV: cytomegalovirus; DARE: digital anorectal examination; ESD: endoscopic submucosal dissection; GBM: gay and bisexual men; HIV: human immunodeficiency virus; HPV: human papilloma virus; HRA: high-resolution anoscopy; HSIL: high grade squamous intraepithelial lesion; IANS: International Anal Neoplasia Society; LSIL: low grade squamous intraepithelial lesion; MSM: men who have sex with men; MSW: men who have sex with women; PAIN: perianal intraepithelial neoplasia; PLWH: persons living with HIV; p16<sup>INK4a</sup>: cyclin-dependent kinase inhibitor 2A; Rb: retinoblastoma protein; RFA: radiofrequency ablation; SCC: squamous cell carcinoma; SISCCA: superficially invasive squamous cell carcinoma; SOTR: solid organ transplant recipient; URR: upstream regulatory region; VIN: vulval intraepithelial neoplasia; VAIN: vaginal intraepithelial neoplasia

### Introduction

Anal cancer is an uncommon malignancy, comprising only 2.5% of all gastrointestinal malignancies. However in certain specific at-risk populations such as men who have sex with men (MSM) living with HIV, there has been an up to 3-fold increased incidence seen over the last

few decades (1). Similar to cervical cancer, the human papillomavirus (HPV) is responsible for the majority of anal cancers (2). Although international practice is increasingly towards active screening for anal cancer precursors in at-risk groups, currently no organised screening program is in effect in Belgium.

### Human papillomavirus

The human papillomavirus (HPV) is a small (55 nm) envelope protein-free double-stranded DNA member of the Papillomaviridae. It is thought that species of papillomavirus have existed for more than 330 million years and HPV is therefore one of the oldest and best-adapted viruses (3). The HPV genome (approximately 7900 base pairs) contains an upstream regulatory region (URR) and 8 sequences encoding 6 early (E) proteins and 2 late (L) proteins (4). It exists in 2 forms, episomal and linear. Most commonly, the circular episomal genome replicates autonomously in the host cell nucleus but is not incorporated in the host DNA. Upon as yet unknown conditions, the HPV genome linearizes, integrates in the host genome and stimulates the expression of E6/E7 proteins (5). Therefore HPV is often divided by oncogenic risk into low-risk genotypes (mainly episomal HPV-6 and HPV-11) and high-risk genotypes (mainly integrated HPV-16 and HPV-18) (6).

HPV has a specific tropism for the skin and anogenital mucosa giving rise to warts but also to premalignant high grade squamous intraepithelial lesions (HSIL) and invasive neoplasia dependent on the genotype (7). The virus enters the epithelium (skin or transitional mucosa) mainly via micro-abrasions and selectively infects transient amplifying (stem) cells at the basal layer of the skin/epithelium. Upon infection HPV immortalizes these transient amplifying cells giving rise to uncontrolled cell proliferation (8). The most important HPV proteins

Correspondence to: Philip Roelandt MD PhD, Department of Gastro-enterology and Hepatology, UZ Leuven, Leuven, Belgium. Phone: +32 16/34.42.25. Fax: +32 16/34.42.19. Email: philip.roelandt@uzleuven.be

Submission date: 22/06/2022  
Acceptance date: 26/07/2022

for immortalization are E6 and E7 because of their interaction with host p53 and retinoblastoma (Rb) protein. In normal non-infected cells both p53 and Rb control the transit from G0/G1 phase to S phase: in case of chromosomal damage, cell growth is halted and DNA can be repaired. Upon binding of E6, p53 is degraded leading to uncontrolled cell proliferation and accumulation of chromosomal defects. On top of this effect, binding of E7 to Rb releases E2F transcription factor from the Rb/E2F complex, allowing defective DNA containing cells to bypass cell arrest. Besides effects on p53 and Rb proteins E7 also interacts with many other proteins (e.g. p21, p27) leading to further growth stimulation (9). These proteins can be used as potential biomarkers. For example p16<sup>INK4a</sup>, a tumor suppressor protein that facilitates the re-binding of pRb to E2F thereby slowing down cell cycle, is overexpressed in HPV-associated premalignant lesions (10).

### Epidemiology of anal HPV infection

The most consistent predictor of anogenital HPV infection in both women and men is sexual activity and the risk is directly related to the number of sexual partners. Anal intercourse is not a consistent risk factor for anal HPV infection as this is not required for transmission since the virus can also spread to the anal region via skin contact or from other genital organs infected with HPV (11).

In women the world-wide prevalence of persistent cervical HPV infection is on average approximately 10% with prevalence ranging from 6.6% in Europe up to 22.9% in Africa with HPV-16 and HPV-18 as most common genotypes. Similar prevalence for anal HPV infection in women is documented (up to 30%)(12,13). The presence of cervical HPV infection also increases the risk of anal HPV infection, as does the presence of anal fissure or > 4 sex partners (14,15). Anal HPV infections are asymptomatic and usually transient. Most anal infections are estimated to be cleared within 3 years albeit HPV-16 is more difficult to clear (16,17). The prevalence of cervical HPV infection starts to decrease from the age of 30, leaving women with persistent infection at highest risk for cervical neoplasia and cancer (18). While HPV infection clears from the cervix in women eventually, it often remains persistent in the anus, leading to a longer lead time from infection to neoplasia in the anus in women (median 20 years between cervical neoplasia and anal neoplasia) (19).

In men who have sex with women (MSW) HPV infection is common with prevalence of genital HPV infection up to 53%, while anal HPV infection is only 12-14% (13,20,21). However, the incidence of anal HPV infection in men who have sex with men (MSM) is as high as 64%, including 35% high-risk HPV-16 (13,22).

In both women and men, HIV-positivity is associated with higher prevalence of HPV infection (69-72% HIV+ HPV+ vs 31-43% HIV- HPV+) and decreased likelihood

of clearance of HPV infection (23). Cumulative risk is well documented, given the prevalence of anal HPV as high as 93% in HIV-positive MSM, including 74% high-risk HPV (22,24). On one hand there is evidence that effective combined antiretroviral therapy (cART) reduces the risk of HPV infection and neoplasia. Although for many years anal cancer incidence continued to climb in this high risk group there is currently some evidence that anal cancer incidence is starting to plateau and expected to fall future with better antiretroviral control (25).

Similar HPV genotypes are found in anal compared to cervical carcinoma however HIV positivity is associated with the presence of multiple HPV strains (73% in HIV+ vs 23% in HIV-) (6).

*In vitro* it has been shown – even at single protein level – that HIV infection (more specifically, tat1 protein) can modulate HPV infection (increased E6/E7 expression)(26). As mentioned earlier, HPV can also lead to neoplasia, however the exact mechanism remains unclear. It is already known that neither the single proteins nor the combination of E6/E7 proteins is sufficient to progress from immortalization to malignant transformation. Therefore it is most likely that changes in host signalling pathways (via cytokine release) and/or mutations (via chromosomal instability) are necessary to transform immortalized cells to malignancy (27). Complementary effects of host and viral factors have already been shown, as E7 stimulates p53<sup>WT</sup>-containing cells to apoptosis while p53<sup>mut</sup>-containing cells are favoured by an anti-apoptotic effect (28).

### Anal cancer

Although anal cancer is still a relatively rare disease, the rate of anal squamous cancer is increasing by about 2% per year (29). The absolute increase in the number of persons living with HIV (PLWH) and organ transplant recipients in combination with an increase in life expectancy in both populations can only partially explain the increasing incidence of anal cancer (2,30).

Patients at risk for anal cancer include PLWH, MSM, women diagnosed with HPV-related gynaecological precancerous lesions or cancer, solid organ transplant recipients (SOTR), patients with autoimmune diseases as well as smokers (31-37). One of the common links between patients at risk is an immunocompromised status (viral or anti-rejection medication). It has been shown that PLWH have a general increased risk of developing cancer (38). The risk of anal cancer is 46-78-fold higher in HIV-positive MSM compared to the general population (22,39,40) and is as high as the risk of colorectal cancer in the general population (cumulative incidence 1.5%)(38).

In solid organ transplant recipients (SOTR) and patients on long-term steroids there is increasing evidence that there is also an increased risk for anal neoplasia and cancer (37,41). Whether there is a correlation between HPV genotype/cancer risk and type of transplanted organ

or type of immunosuppressive medication is currently unknown, although studies suggesting differential risk are arising (42).

**Anal precursor lesions**

Often precursor lesions remain asymptomatic until malignant transformation and/or invasion occurs. In resection specimens after hemorrhoidectomy between 2003 and 2019, anal intraepithelial neoplasia (AIN) was found incidentally in 54 of 1612 cases (3.4%) with increasing detection of high-grade lesions in the more recent years (43). A recent retrospective study in patients with anal cancer showed that anal precursor lesions were found in 34% of HIV-positive patients compared to only 3% in HIV-negative patients (32). In line with the known increase in the rate of anal squamous cell cancer, an even more pronounced rise in AIN (up to 11% per year) was noted (29).

The diagnosis is confirmed on histology of the biopsy or resection specimen. Based on the extent of dysplastic cells in the epithelial layer on a biopsy, precursor lesions can be divided into AIN1, AIN2 and AIN3 and should be reported accordingly in the pathological report (44). Although this is still required, a division is made between high grade squamous intraepithelial lesions (HSIL) considered to be precancerous, and low grade squamous intraepithelial lesions (LSIL) representing proliferative infection alone. Additional p16 immunostaining in case of AIN2 distinguishes between HSIL and LSIL thereby reducing unnecessary treatments (45).

Additional characterisation including Ki67 immunostaining, methylation status and HPV-E4 positivity are currently being tested but at present their usefulness is unclear (46). Progression rate from AIN to cancer is thought to be approximately 10% with a median time of 2.7 years (29). The exact discriminating characteristics of these progressing lesions remain unclear. A recent large randomised controlled trial was stopped early due to the effectiveness of anal HSIL treatment in the prevention of anal cancer (47). Hence screening and surveillance of anal HSIL with treatment will increasingly become crucial.

**Screening techniques**

International experts advise to actively screen for anal intraepithelial neoplasia in specific risk populations but due to the lack of large randomised control trials there is high variation in the management of anal cancer screening: half of clinics use cytology followed by high-

resolution anoscopy (HRA), while the other half uses immediate HRA (48,49).

By far the easiest and most universally available screening technique for anal cancer is digital anorectal examination (DARE). This technique allows detection of palpable abnormalities in the distal rectum, anal canal and perianal skin and should therefore not be forgotten among the arsenal of more invasive or complex screening techniques (50).

Analogous to cervical cytology, anal cytology can be easily obtained using a classical cytobrush, and liquid based cytology. Anal cytology should be obtained prior to performing DARE and with no or water-only lubricant to obtain technically satisfactory samples. The unsatisfactory rate should be no higher than 5% in MSM living with HIV (51). Cytology should be reported according to the Bethesda classification, normal, atypical squamous cells of unknown significance (ASCUS), LSIL or HSIL. The biggest drawback of anal cytology is the lower specificity (range 37-76%) and sensitivity (range 54-89%) compared to cervical cytology (52) and the higher susceptibility to crush artefacts due to the specific anatomical position of the anal transition zone. Abnormal anal cytology was found in more than 30% of women with a history of high-grade cervical lesions or cancer, of which 31.3% had biopsy-proven AIN on high-resolution anoscopy (HRA) (33).

Besides Papanicolaou immunostaining and bright field microscopy, HPV can be detected in anal cytology samples by PCR (DNA or RNA) or downstream cellular markers (p16/Ki67) (53). A combined p16/Ki67 immunostaining might even have a higher sensitivity for detection of AIN in HIV-positive MSM (54). A recent study showed that the combination of HPV PCR testing in combination with cytology has the highest sensitivity (91.7%) of detecting high-grade AIN (55,56).

High resolution anoscopy (HRA) should be performed by adequately trained clinicians using a classical anoscope and colposcope. The entire anal transition zone with squamocolumnar junction needs to be visualized, as well as the anal canal and the perianal skin. Enhancing contrast using 5% acetic acid is used to detect dysplastic lesions often in combination with Lugol's solution. Abnormal findings (e.g. acetowhite lesions, specific vascular patterns) should be biopsied selectively and reported accordingly (51).

International guidelines suggest that patients at risk (PLWH, MSM, woman diagnosed with HPV-related gynaecological precancerous lesions or cancer, SOTR, patients with autoimmune diseases) should be clinically evaluated annually with DARE, cytology analysis and

AIN1	AIN2 p16 <sup>-</sup>	AIN2 p16 <sup>+</sup>	AIN3	SISCCA	Invasive carcinoma
Dysplasia lower 1/3	Dysplasia lower 2/3	Dysplasia lower 2/3	Full thickness dysplasia	< 7 mm width and < 3 mm depth	> 7 mm width or > 3 mm depth
Low-grade squamous intraepithelial lesion (LSIL)		High-grade squamous intraepithelial lesion (HSIL)		Carcinoma	

HRA (51,57). The interval for screening in patients at lower risk, defined as normal cytology and HPV16-negative at baseline, can potentially be increased to 3 years although there is poor quality of evidence at present to guide ideal follow-up protocols (58).

### Treatment

In HIV-positive MSM, detection of precursor lesions is common, both for low-grade and high-grade lesions (up to 43%) (59,60). Nearly half of the low-grade lesions was cleared spontaneously while only a small proportion progressed to high-grade lesions (61). Robust data that treatment of high-grade lesions prevents progression to anal cancer are yet to be published, however a recent large international randomised controlled trial (ANCHOR study, [www.anchorstudy.org](http://www.anchorstudy.org)) was closed early due to effectiveness of treatment in preventing anal SCC (47). It has been generally agreed that high-grade AIN (p16<sup>+</sup> AIN2 or AIN3) should be treated, however high-grade AIN is difficult to treat due to HPV persistence in immunocompromised patients and high recurrence rates (48). Moreover, even high-grade precursor lesions in gay and bisexual men (GBM) can clear spontaneously (average 22 per 100 person-years), mainly in patients < 45 years and in the absence of HPV-16. In this study, AIN2 was also more likely to clear than AIN3 (60).

However, no consensus on the optimal treatment for AIN2/3 is currently available despite international guidelines from large societies (49,62,63). Infrared coagulation, laser and electrocautery appears a good option for AIN (64-66) but also have a high recurrence rate and logistic limitations such as the need for equipment, training and a suitable outpatient setting. Many groups use as an alternative, off-licence drugs known for their efficacy in external anogenital warts (so-called condylomata accuminata caused by low-risk HPV):

- Imiquimod is an immunomodulatory agent known to be efficient in anogenital warts. Meta-analysis showed an overall response rate of AIN to 5% imiquimod cream of 82% (complete response 48%, partial response 34%) but also a recurrence rate of 36% (67). However, detailed analysis revealed good response of perianal AIN to imiquimod, while the response rate of intra-anal AIN was only 37% (complete response 22%, partial response 15%) with a recurrence rate of 71% after 72 weeks (68).
- Cidofovir is a direct antiviral agent also used to treat cytomegalovirus (CMV) infections in immunocompromised patients. Topical 1% cidofovir crème was applied to high-grade squamous perianal intraepithelial neoplasia (PAIN) and vaginal intraepithelial neoplasia (VAIN) in HIV-positive individuals for 12 weeks. In 51% of the patients improvement was documented, while 21% of the patients were found to have stable disease (69).

- Topical application of 5-fluorouracil (a well-known pyrimidine analogue antimetabolite) resulted in complete response rate of 17-39% in AIN in HIV-positive men but again with a high recurrence rate (58% after 72 weeks)(68, 70).
- Sinecatechins (10% or 15%) have no data regarding use in HSIL but have equivalent efficacy to imiquimod in the use of warts.

One prospective study revealed that electrocautery was still superior compared to imiquimod and 5-fluorouracil in treating AIN (63% of HIV-positive MSM), however recurrence was comparably high in all arms of this small RCT (resp. 68%, 71% and 58%) (68). Finally the value of post-exposure vaccination is currently being investigated after initial beneficial results on incidence of HSIL in young asymptomatic MSM (reduction of AIN2/3 by 54%) (71) that was not reproduced when repeated in an older cohort (PLWH > 26 years) (72). Recently it was shown in a pilot study of 10 patients that hemi-circumferential radiofrequency ablation (RFA) resulted in a high rate of AIN2/3 eradication (73). Endoscopic submucosal dissection (ESD) of relatively large lesions can also be performed (74).

A recent systematic review confirms the lack of sufficient evidence to propose one of the above mentioned options as the gold standard, and confirms the high recurrence rate in HIV-positive populations (75). Therefore a combination of an ablative and topical treatment appears acceptable. A 6-monthly follow-up interval (with clinical observation without regular cytology, HPV testing or HRA) was weakly recommended in 2018 (63), but the results of the recent ANCHOR study (including 6-monthly follow-up after treatment) will probably change the clinical practice in the near future (47).

### Situation in Belgium

Since 2010-2011 vaccination programmes for girls between 12 and 14 years have commenced, resulting in variable coverage between the different regions (91% Flanders 2016, 36-50% Brussels-Wallonia 2017). In July 2017 the Belgian Superior Health Council advised to extend the vaccination for both girls and boys between 9 and 14 years. In Flanders this advice was implemented in 2019 with the reimbursement of vaccination of 12-years-old boys. Despite the start of vaccination, screening programmes are necessary as it is estimated that preventive vaccination will reduce the incidence of anal cancer by 2050-2060.

Currently there is no official countrywide organised screening program in Belgium. Patients are frequently being referred to a selected number of physicians trained in HRA based on clinical findings (e.g. lesion detected during colonoscopy) or histopathological findings (e.g. hemorrhoidectomy specimen). Local screening initiatives also include referring asymptomatic HIV-

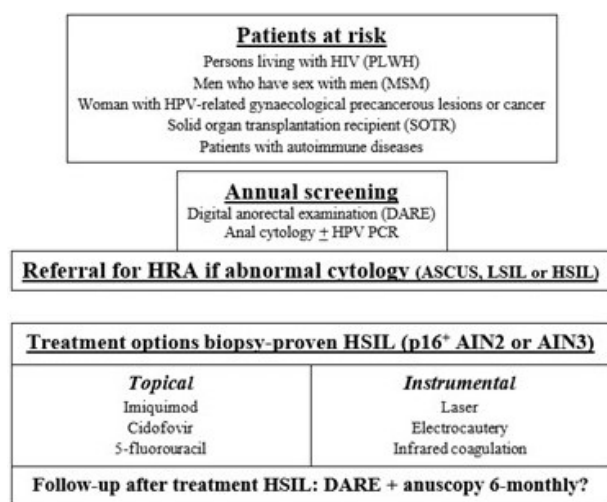


Figure 1. — Populations at-risk, screening and treatment options of anal intraepithelial lesions. AIN = anal intraepithelial neoplasia; ASCUS = atypical squamous cells of unknown significance; HPV = human papilloma virus; HRA = high-resolution anoscopy; HSIL = high grade squamous intraepithelial lesion; LSIL = low grade squamous intraepithelial lesion.

positive patients for HRA based on yearly DARE and/or anal cytology.

In 2016 international guidelines were published on minimum standards to detect premalignant anal lesions (51), while American, British and Italian guidelines have been updated recently (62,63,76). Despite the current lack of evidence on the effectiveness of treating high-grade lesions, all guidelines advice access to HRA services for physicians caring for high-risk populations. Therefore it is evident that commencing screening and diagnostic services (including HRA) in Belgium should use these guidelines as a starting point.

It is clear that PLWH (MSM, non-MSM as well as women) as well as SOTR > 10 years after transplantation are at highest risk for AIN and anal cancer (37), therefore commencing screening programs should focus on these 2 populations. In a next phase, screening can be extended to HIV-negative gay and bisexual men (GBM) and women with a history of HPV-related anogenital disease.

Given the current evidence, a combination of anal cytology and DARE with HPV PCR testing could be offered to patients at risk on an annual basis. In case of abnormal findings on cytology (ASCUS, LSIL or HSIL) or digital rectal examination patients should be referred for HRA, followed by biopsy and/or treatment if indicated (Figure 1). The incidence rate of anal cancer in PLWH (women 22 per 100.000 patient years, MSM 85 per 100.000 patient years) is comparable to already reimbursed screening programs such as cervical cancer (30-40 per 100.000 patient years) or colorectal cancer (50 per 100.000 patient years) (37). Therefore reimbursement of all above mentioned techniques in organised anal cancer screening program will be discussed with the Federal Public Service Public Health and the National

Institute for Health and Disability Insurance (RIZIV-INAMI).

## Conclusions

Anal intraepithelial neoplasia and anal cancer is an emerging problem as HPV infection remains frequent and the populations at risk (PLWH, MSM, woman diagnosed with HPV-related gynaecological precancerous lesions or cancer, SOTR, patients with autoimmune diseases) are increasing gradually. Therefore, organised screening in Belgium should be commenced as soon as possible to provide the best preventive care for patients at risk.

## References

- NELSON R.A., LEVINE A.M., BERNSTEIN L., SMITH D.D., LAI L.L. Changing patterns of anal canal carcinoma in the United States. *J Clin Oncol.* 2013; **31**:1569-75.
- DESHMUKH A.A., SUK R., SHIELS M.S., *et al.* Recent Trends in Squamous Cell Carcinoma of the Anus Incidence and Mortality in the United States, 2001-2015. *J Natl Cancer Inst.* 2020; **112**:829-38.
- BENTON M.J., DONOGHUE P.C. Paleontological evidence to date the tree of life. *Mol Biol Evol.* 2007; **24**:26-53.
- CHOUHY D., BOLATTI E.M., PEREZ G.R., GIRI A.A. Analysis of the genetic diversity and phylogenetic relationships of putative human papillomavirus types. *J Gen Virol.* 2013; **94**:2480-8.
- SCHWARZ E., FREESE U.K., GISSMANN L., *et al.* Structure and transcription of human papillomavirus sequences in cervical carcinoma cells. *Nature.* 1985; **314**:111-4.
- PARTRIDGE J.M., KOUTSKY L.A. Genital human papillomavirus infection in men. *Lancet Infect Dis.* 2006; **6**:21-31.
- CARR J., GYORFI T. Human papillomavirus. Epidemiology, transmission, and pathogenesis. *Clin Lab Med.* 2000; **20**:235-55.
- ALDABAGH B., ANGELES J.G., CARDONES A.R., ARRON S.T. Cutaneous squamous cell carcinoma and human papillomavirus: is there an association? *Dermatol Surg.* 2013; **39**:1-23.
- MOODY C.A., LAIMINS L.A. Human papillomavirus oncoproteins: pathways to transformation. *Nat Rev Cancer.* 2010; **10**:550-60.
- DYSON N., HOWLEY P.M., MÜNGER K., HARLOW E. The human papilloma virus-16 E7 oncoprotein is able to bind to the retinoblastoma gene product. *Science.* 1989; **243**:934-7.
- WIDDICE L.E., BRELAND D.J., JONTE J., *et al.* Human papillomavirus concordance in heterosexual couples. *J Adolesc Health.* 2010; **47**:151-9.
- DE SANJOSÉ S., DIAZ M., CASTELLSAGUÉ X., *et al.* Worldwide prevalence and genotype distribution of cervical human papillomavirus DNA in women with normal cytology: a meta-analysis. *Lancet Infect Dis.* 2007; **7**:453-9.
- GIULIANO A.R., NYITRAY A.G., KREIMER A.R., *et al.* EUROGIN 2014 roadmap: differences in human papillomavirus infection natural history, transmission and human papillomavirus-related cancer incidence by gender and anatomic site of infection. *Int J Cancer.* 2015; **136**:2752-60.
- GOODMAN M.T., SHVETSOV Y.B., MCDUFFIE K., *et al.* Acquisition of anal human papillomavirus (HPV) infection in women: the Hawaii HPV Cohort study. *J Infect Dis.* 2008; **197**:957-66.
- CASTRO F.A., QUINT W., GONZALEZ P., *et al.* Prevalence of and risk factors for anal human papillomavirus infection among young healthy women in Costa Rica. *J Infect Dis.* 2012; **206**:1103-10.
- MOSCICKI A.B., MA Y., FARHAT S., *et al.* Natural history of anal human papillomavirus infection in heterosexual women and risks associated with persistence. *Clin Infect Dis.* 2014; **58**:804-11.
- POYNTEN I.M., JIN F., GARLAND S.M., *et al.* HIV, Immune Dysfunction, and the Natural History of Anal High-Risk Human Papillomavirus Infection in Gay and Bisexual Men. *J Infect Dis.* 2021; **224**:246-57.
- WRIGHT T.C., JR., SCHIFFMAN M. Adding a test for human papillomavirus DNA to cervical-cancer screening. *N Engl J Med.* 2003; **348**:489-90.
- STIER E.A., CHIAO E.Y. Anal Cancer and Anal Cancer precursors in Women with a History of HPV-Related Dysplasia and Cancer. *Semin Colon Rectal Surg.* 2017; **28**:97-101.
- NYITRAY A.G., DA SILVA R.J., BAGGIO M.L., *et al.* The prevalence of genital HPV and factors associated with oncogenic HPV among men having

- sex with men and men having sex with women and men: the HIM study. *Sex Transm Dis.* 2011; **38**:932-40.
21. NYITRAY A.G., CARVALHO DA SILVA R.J., BAGGIO M.L., *et al.* Age-specific prevalence of and risk factors for anal human papillomavirus (HPV) among men who have sex with women and men who have sex with men: the HPV in men (HIM) study. *J Infect Dis.* 2011; **203**:49-57.
  22. MACHALEK D.A., POYNTEN M., JIN F., *et al.* Anal human papillomavirus infection and associated neoplastic lesions in men who have sex with men: a systematic review and meta-analysis. *Lancet Oncol.* 2012; **13**:487-500.
  23. MBULAWA Z.Z., MARAIS D.J., JOHNSON L.F., COETZEE D., WILLIAMSON A.L. Impact of human immunodeficiency virus on the natural history of human papillomavirus genital infection in South African men and women. *J Infect Dis.* 2012; **206**:15-27.
  24. DONÀ M.G., GIULIANI M., ROLLO F., *et al.* Incidence and clearance of anal high-risk Human Papillomavirus infection and their risk factors in men who have sex with men living with HIV. *Sci Rep.* 2022; **12**:184.
  25. BLASER N., BERTISCH B., KOUYOS R.D., *et al.* Impact of screening and antiretroviral therapy on anal cancer incidence in HIV-positive MSM. *AIDS.* 2017; **31**:1859-66.
  26. VERNON S.D., HART C.E., REEVES W.C., ICENOGLE J.P. The HIV-1 tat protein enhances E2-dependent human papillomavirus 16 transcription. *Virus Res.* 1993; **27**:133-45.
  27. ZUR HAUSEN H. Papillomaviruses causing cancer: evasion from host-cell control in early events in carcinogenesis. *J Natl Cancer Inst.* 2000; **92**:690-8.
  28. STOREY A., THOMAS M., KALITA A., *et al.* Role of a p53 polymorphism in the development of human papillomavirus-associated cancer. *Nature.* 1998; **393**:229-34.
  29. LEE G.C., KUNITAKE H., MILCH H., *et al.* What Is the Risk of Anal Carcinoma in Patients With Anal Intraepithelial Neoplasia III? *Dis Colon Rectum.* 2018; **61**:1350-6.
  30. VAN DER ZEE R.P., RICHEL O., DE VRIES H.J., PRINS J.M.. The increasing incidence of anal cancer: can it be explained by trends in risk groups? *Neth J Med.* 2013; **71**:401-11.
  31. FRISCH M., OLSEN J.H., MELBYE M. Malignancies that occur before and after anal cancer: clues to their etiology. *Am J Epidemiol.* 1994; **140**:12-9.
  32. BROGDEN D.R.L., KHOO C.C., KONTOVOUNISIOS C., *et al.* Anal squamous cell carcinoma in a high HIV prevalence population. *Discov Oncol.* 2021; **12**:3.
  33. WOHLMUTH C., GHORAB Z., SHIER M., *et al.* Cytology-based screening for anal intraepithelial neoplasia in women with a history of cervical intraepithelial neoplasia or cancer. *Cancer Cytopathol.* 2021; **129**:140-7.
  34. HOLLY E.A., WHITTEMORE A.S., ASTON D.A., AHN D.K., NICKOLLOFF B.J., KRISTIANSEN J.J. Anal cancer incidence: genital warts, anal fissure or fistula, hemorrhoids, and smoking. *J Natl Cancer Inst.* 1989; **81**:1726-31.
  35. KNIGHT K., AL-WAHID M., CHOONG J.X., *et al.* Multidisciplinary management of anal intraepithelial neoplasia and rate of progression to cancer: A retrospective cohort study. *Eur J Surg Oncol.* 2021; **47**:304-10.
  36. POWER FOLEY M., KELLY M.E., KERR C., *et al.* Management of anal intraepithelial neoplasia and anal squamous cell carcinoma at a tertiary referral centre with a dedicated infectious diseases unit: an 18-year review. *Int J Colorectal Dis.* 2020; **35**:1855-64.
  37. CLIFFORD G.M., GEORGES D., SHIELDS M.S., *et al.* A meta-analysis of anal cancer incidence by risk group: Toward a unified anal cancer risk scale. *Int J Cancer.* 2021; **148**:38-47.
  38. SILVERBERG M.J., LAU B., ACHENBACH C.J., *et al.* Cumulative Incidence of Cancer Among Persons With HIV in North America: A Cohort Study. *Ann Intern Med.* 2015; **163**:507-18.
  39. DALING J.R., WEISS N.S., KLOPFENSTEIN L.L., COCHRAN L.E., CHOW W.H., DAIFUKU R. Correlates of homosexual behavior and the incidence of anal cancer. *JAMA.* 1982; **247**:1988-90.
  40. VAN DER ZEE R.P., RICHEL O., VAN NOESEL C.J.M., *et al.* Cancer Risk Stratification of Anal Intraepithelial Neoplasia in Human Immunodeficiency Virus-Positive Men by Validated Methylation Markers Associated With Progression to Cancer. *Clin Infect Dis.* 2021; **72**:2154-63.
  41. ALBUQUERQUE A., STIRRUP O., NATHAN M., CLIFFORD G.M. Burden of anal squamous cell carcinoma, squamous intraepithelial lesions and HPV16 infection in solid organ transplant recipients: A systematic review and meta-analysis. *Am J Transplant.* 2020; **20**:3520-8.
  42. ROELANDT P., DROOGNE W., VÖRÖS G., VAN AELST L., REGA F., VAN CLEEMPOT J. Are heart transplant recipients more at risk for anal squamous carcinoma than other solid organ transplant recipients? *Int J Cancer.* 2022; **151**:156-7.
  43. NAVALE P., GONZALEZ R.S., VYAS M. Incidental secondary findings in hemorrhoidectomy specimens: a 16-year experience from a single academic center. *Hum Pathol.* 2021; **109**:12-20.
  44. DARRAGH T.M., COLGAN T.J., COX J.T., *et al.* The Lower Anogenital Squamous Terminology Standardization Project for HPV-Associated Lesions: background and consensus recommendations from the College of American Pathologists and the American Society for Colposcopy and Cervical Pathology. *Arch Pathol Lab Med.* 2012; **136**:1266-97.
  45. LIU Y., MCCLUGGAGE W.G., DARRAGH T.M., *et al.* Classifying Anal Intraepithelial Neoplasia 2 Based on LAST Recommendations. *Am J Clin Pathol.* 2021; **155**:845-52.
  46. VAN DER ZEE R.P., MEIJER C.J.L.M., CUMING T., *et al.* Characterisation of anal intraepithelial neoplasia and anal cancer in HIV-positive men by immunohistochemical markers p16, Ki-67, HPV-E4 and DNA methylation markers. *Int J Cancer.* 2021; **149**:1833-1844.
  47. PALEFSKY J.M., LEE J.Y., JAY N., *et al.* Treatment of Anal High-Grade Squamous Intraepithelial Lesions to Prevent Anal Cancer. *N Engl J Med.* 2022; **386**:2273-82.
  48. PATEL J., SALIT I.E., BERRY M.J., *et al.* Environmental scan of anal cancer screening practices: worldwide survey results. *Cancer Med.* 2014; **3**:1052-61.
  49. KOSKAN A.M., BRENNHOFER S.A., HELITZER D.L. Screening for anal cancer precursors among patients living with HIV in the absence of national guidelines: practitioners' perspectives. *Cancer Causes Control.* 2019; **30**:989-96.
  50. HILLMAN R.J., BERRY-LAWHORN J.M., ONG J.J., *et al.* International Anal Neoplasia Society Guidelines for the Practice of Digital Anal Rectal Examination. *J Low Genit Tract Dis.* 2019; **23**:138-46.
  51. HILLMAN R.J., CUMING T., DARRAGH T., *et al.* 2016 IANS International Guidelines for Practice Standards in the Detection of Anal Cancer Precursors. *J Low Genit Tract Dis.* 2016; **20**:283-91.
  52. ALBUQUERQUE A., RIOS E., SCHMITT F. Recommendations Favoring Anal Cytology as a Method for Anal Cancer Screening: A Systematic Review. *Cancers (Basel).* 2019; **11**:1942.
  53. IKENBERG H., BERGERON C., SCHMIDT D., *et al.* Screening for cervical cancer precursors with p16/Ki-67 dual-stained cytology: results of the PALMS study. *J Natl Cancer Inst.* 2013; **105**:1550-7.
  54. CHEN C.C., HSUEH K.C., SHEN C.H., BAI C.H., WU C.C., WANG Y.H. The Diagnostic Value of p16/Ki67 Dual Immunostaining for Anal Intraepithelial Neoplasia: A Meta-Analysis. *Am J Mens Health.* 2020; **14**:1557988320977630.
  55. SWANSON A.A., HARTLEY C., LONG M.E., *et al.* Evaluation of high-risk human papillomavirus testing and anal cytology to detect high-grade anal intraepithelial neoplasia. *J Am Soc Cytopathol.* 2021; **10**:406-13.
  56. GAISA M.M., SIGEL K.M., DESHMUKH A.A., *et al.* Comparing Anal Cancer Screening Algorithms Using Cytology and Human Papillomavirus DNA Testing in 3 High-Risk Populations. *J Infect Dis.* 2021; **224**:881-8.
  57. BULL-HENRY K., MORRIS B., BUCHWALD U.K.. The importance of anal cancer screening and high-resolution anoscopy to gastroenterology practice. *Curr Opin Gastroenterol.* 2020; **36**:393-401.
  58. MOREAU J., SIPROUDHIS L., BROCHARD C., *et al.* Improving the screening of precancerous anal lesions in high-risk subjects with normal cytology: A longitudinal cohort study using simple tests. *Dig Liver Dis.* 2020; **52**:1359-64.
  59. WEI F., GAISA M.M., D'SOUZA G., *et al.* Epidemiology of anal human papillomavirus infection and high-grade squamous intraepithelial lesions in 29900 men according to HIV status, sexuality, and age: a collaborative pooled analysis of 64 studies. *Lancet HIV.* 2021; **8**:e531-e43.
  60. POYNTEN I.M., JIN F., ROBERTS J.M., *et al.* The Natural History of Anal High-grade Squamous Intraepithelial Lesions in Gay and Bisexual Men. *Clin Infect Dis.* 2021; **72**:853-61.
  61. JONGEN V.W., RICHEL O., MARRA E., *et al.* Anal Squamous Intraepithelial Lesions (SILs) in Human Immunodeficiency Virus-Positive Men Who Have Sex With Men: Incidence and Risk Factors of SIL and of Progression and Clearance of Low-Grade SILs. *J Infect Dis.* 2020; **222**:62-73.
  62. GEH I., GOLLINS S., RENEHAN A., *et al.* Association of Coloproctology of Great Britain & Ireland (ACPGBI): Guidelines for the Management of Cancer of the Colon, Rectum and Anus (2017) - Anal Cancer. *Colorectal Dis.* 2017; **19** Suppl 1:82-97.
  63. STEWART D.B., GAERTNER W.B., GLASGOW S.C., *et al.* The American Society of Colon and Rectal Surgeons Clinical Practice Guidelines for Anal Squamous Cell Cancers (Revised 2018). *Dis Colon Rectum.* 2018; **61**:755-74.
  64. GOLDSTONE R.N., GOLDSTONE A.B., RUSS J., GOLDSTONE S.E. Long-term follow-up of infrared coagulator ablation of anal high-grade dysplasia in men who have sex with men. *Dis Colon Rectum.* 2011; **54**:1284-92.
  65. BURGOS J., CURRAN A., LANDOLFI S., *et al.* The effectiveness of electrocautery ablation for the treatment of high-grade anal intraepithelial neoplasia in HIV-infected men who have sex with men. *HIV Med.* 2016; **17**:524-531.

66. JOHNSTONE A.A., SILVERA R., GOLDSTONE S.E. Targeted ablation of perianal high-grade dysplasia in men who have sex with men: an alternative to mapping and wide local excision. *Dis Colon Rectum*. 2015; **58**:45-52.
67. MAHTO M., NATHAN M., O'MAHONY C. More than a decade on: review of the use of imiquimod in lower anogenital intraepithelial neoplasia. *Int J STD AIDS*. 2010; **21**:8-16.
68. RICHEL O., DE VRIES H.J., VAN NOESEL C.J., DIJKGRAAF M.G., PRINS J.M. Comparison of imiquimod, topical fluorouracil, and electrocautery for the treatment of anal intraepithelial neoplasia in HIV-positive men who have sex with men: an open-label, randomised controlled trial. *Lancet Oncol*. 2013; **14**:346-53.
69. STIER E.A., GOLDSTONE S.E., EINSTEIN M.H., *et al*. Safety and efficacy of topical cidofovir to treat high-grade perianal and vulvar intraepithelial neoplasia in HIV-positive men and women. *AIDS*. 2013; **27**:545-51.
70. RICHEL O., WIELAND U., DE VRIES H.J., *et al*. Topical 5-fluorouracil treatment of anal intraepithelial neoplasia in human immunodeficiency virus-positive men. *Br J Dermatol*. 2010; **163**:1301-7.
71. PALEFSKY J.M., GIULIANO A.R., GOLDSTONE S., *et al*. HPV vaccine against anal HPV infection and anal intraepithelial neoplasia. *N Engl J Med*. 2011; **365**:1576-85.
72. WILKIN T.J., CHEN H., CESPEDES M.S., *et al*. A Randomized, Placebo-Controlled Trial of the Quadrivalent Human Papillomavirus Vaccine in Human Immunodeficiency Virus-Infected Adults Aged 27 Years or Older: AIDS Clinical Trials Group Protocol A5298. *Clin Infect Dis*. 2018; **67**:1339-46.
73. GOLDSTONE R.N., HASAN S.R., DRURY S., DARRAGH T.M., VAN ZANTE A., GOLDSTONE S.E. A trial of radiofrequency ablation for anal intraepithelial neoplasia. *Int J Colorectal Dis*. 2017; **32**:357-65.
74. SANTOS-ANTUNES J., DIAS E., COELHO R., *et al*. High-grade anal intraepithelial neoplasia treated with endoscopic submucosal dissection: a case report. *Acta Gastroenterol Belg*. 2022; **85**:108-10.
75. BROGDEN D.R.L., WALSH U., PELLINO G., KONTOVOUNISIOS C., TEKKIS P., MILLS S.C. Evaluating the efficacy of treatment options for anal intraepithelial neoplasia: a systematic review. *Int J Colorectal Dis*. 2021; **36**:213-26.
76. BINDA G.A., GAGLIARDI G., DAL CONTE I., *et al*. Practice parameters for the diagnosis and treatment of anal intraepithelial neoplasia (AIN) on behalf of the Italian Society of Colorectal Surgery (SICCR). *Tech Coloproctol*. 2019; **23**:513-28.