

The use of autologous peritoneum in surgery of portal hypertension: H-shape splenorenal shunt using simple layer peritoneal tube

N. Terwagne¹, L. Marique¹, A. Dieu², G. Dahlqvist³, L. Coubeau¹

(1) Service de Chirurgie et Transplantation Abdominale, Cliniques Universitaires Saint-Luc, Université catholique de Louvain, Brussels, Belgium; (2) Service d'Anesthésiologie, Cliniques Universitaires Saint-Luc, Université catholique de Louvain, Brussels, Belgium; (3) Service d'Hépatogastro-entérologie, Cliniques Universitaires Saint-Luc, Université catholique de Louvain, Brussels, Belgium.

Abstract

The management of portal hypertension complicated by iterative gastro-intestinal bleeding remains challenging, especially in a low-income environment. Interventional radiology and endoscopic treatments are not always accessible, and a definitive surgical option may prove to be lifesaving. We report a new technique of surgical portosystemic shunt that can be performed in all contexts. We describe the surgical technique of a H-shaped splenorenal shunt using autologous rolled up peritoneum as a vascular graft. (*Acta gastroenterol. belg.*, 2022, 85, 643-645).

Keywords: Portal hypertension, splenorenal shunt, autologous parietal peritoneum

Abbreviations: PH: Portal Hypertension; GI: Gastro-Intestinal; EHPVO: extra-hepatic portal vein obstruction; TIPSS: transjugular intrahepatic portosystemic shunt; SRS: Splenorenal shunt; ICU: intensive care unit.

Introduction

Portal Hypertension (PH) may induce cataclysmic episodes of Gastro Intestinal (GI) bleeding. This condition is secondary to hyperpressure upstream of a resistive liver on the mesenteric-portal network in cirrhotic Portal Hypertension (PH), or of a thrombotic vascular obstacle in Extra Hepatic Portal Vein Obstruction (EHPVO). The standard of care in GI bleeding management is endoscopy and consists of local treatment of gastroesophageal varices using sclerotherapy or ligation. However, such non-preemptive strategy is not definitive with a rebleeding rate of up to 60% within a year. It is moreover associated with a mortality rate of more than 30% in cirrhotic patients (1).

A more perennial approach is to decompress the high-pressure porto-mesenteric pre-hepatic system by connecting it to a low-pressure systemic vascular network in the porto-systemic shunts, or intra-hepatically in the left mesenteric-portal shunt or meso-Rex shunt.

In order to minimize the risk of a complex and haemorrhagic surgery in patients at high risk, interventional radiology techniques have been developed. The transjugular intrahepatic portosystemic shunt (TIPSS) was described in the 1990's (2) but more recent techniques are currently available such as the balloon-occluded retrograde transvenous obliteration or the percutaneous retroperitoneal SplenoRenal Shunt (SRS). However, the

superiority of bypass techniques, whether surgical or radiological, over iterative endoscopic treatment remains debated. The objective disadvantage of endoscopy is the need for multiple sessions, which limits its application in countries with constrained resources where patients do not have easy access to health care centers (3). Similarly, the cost and availability of recent interventional radiology shunt techniques also limits the use of these procedures in these same regions.

We describe hereafter a durable surgical portosystemic shunt, a technique implementable in emerging medical centres and which do not require synthetic vascular material.

Case

Patient was a 49-year-old man with compensated cirrhosis secondary to Caroli disease. His Model for End-Stage Liver Disease (MELD) score was 8 and Child-Pugh A. He has clinically significant portal hypertension confirmed by hepatic venous pressure gradient measurement at 16 mmHg. Endoscopy reveals grade III gastric varices. He had presented with multiple episodes of GI bleeding, lastest with hemorrhagic shock and intensive care unit (ICU) admission.

He also presented with intrahepatic gallstones and recurrent cholangitis. Infected and dilated bile tree was considered as a contraindication to TIPSS placement. We opted for SRS because of the nearness of splenic and renal veins.

Surgery was performed through upper midline incision. The spleen was pushed up and forward, the kidney down and back. The renal vein was dissected over a length of 3 cm and marked on a vessel loop. The splenic vein was located at the upper edge of the tail of the pancreas. It was progressively and partially freed from the pancreatic parenchyma. It is sufficiently individualized to be able

Correspondence to: Laurent Coubeau, MD, Service de Chirurgie et Transplantation Abdominale, Cliniques Universitaires Saint-Luc, Université catholique de Louvain, 10 Avenue Hippocrate, 1200, Brussels, Belgium. Phone: +32 2 764 1483.
Email: laurent.coubeau@uclouvain.be

Submission date: 23/08/2021
Acceptance date: 02/10/2021

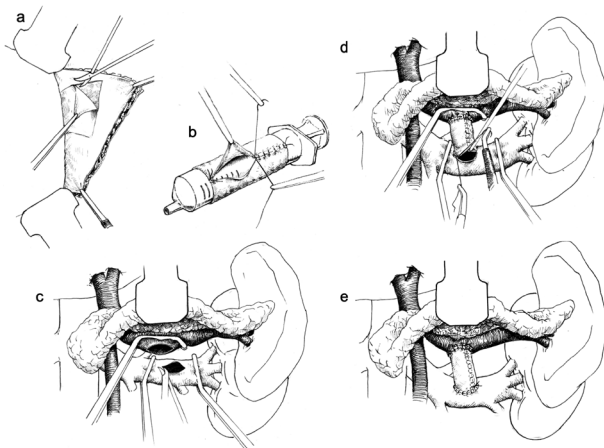


Fig 1. — Operative technique. **a** Harvesting of a peritoneal non-fascial square in the left hypochondrium. **b** Tubular shape suturing using a syringe as a mold. **c** Dissection of the renal and splenic veins: splenic vein is sufficiently freed to be able to perform a lateral clamping. **d** Completion of the two end-to-side anastomoses between the splenic vein, the graft and the renal vein. **e** Final aspect of the H-shaped splenoportal shunt using simple layer autologous peritoneal tube.

to perform a lateral clamping without putting too much traction on adjacent venous collaterals.

Operative technique (Figure 1): A square of parietal peritoneum without fascial backing was harvested from the left hypochondrium. We used low-intensity cautery and putted 4 stitches on the edge. As previously reported, we used a 10 cc syringe as a mold for a vascular tube with mesothelial side positioned toward the lumen. Longitudinal running suture was performed with 6-0 Prolène. Patient received 20U/Kg intraoperative heparin anticoagulation before renal vein cross-clamping. The end-to-side anastomosis between the graft and the renal vein was done first with a 6-0 Prolène. The second anastomosis was subsequently performed between the graft and the side of the splenic vein. Both structures were excessively fragile and the use of a 7-0 Prolene wire mounted on a fine needle being mandatory. Hepatofugal flow in the SRS was measured at 750ml/min intraoperatively with continued doppler probe. Figure 2 illustrates the final intra-operative aspect of the shunt.

The length of hospital stay was 18 days including 4 days in ICU. The Clavien-Dindo grade was I. A CT scan was performed on post-operative day 2 and confirmed patency of the shunt with decrease in spleen size. Two months later, endoscopy revealed residual grade I varices. Long-term follow-up was uneventful with recurring no GI bleeding, whereas vascular MRI confirmed SRS patency 24 months after surgery.

Discussion

Surgery for portal hypertension has progressively been replaced in high-income countries by endoscopic or minimally invasive options. PH in patients with cirrhosis

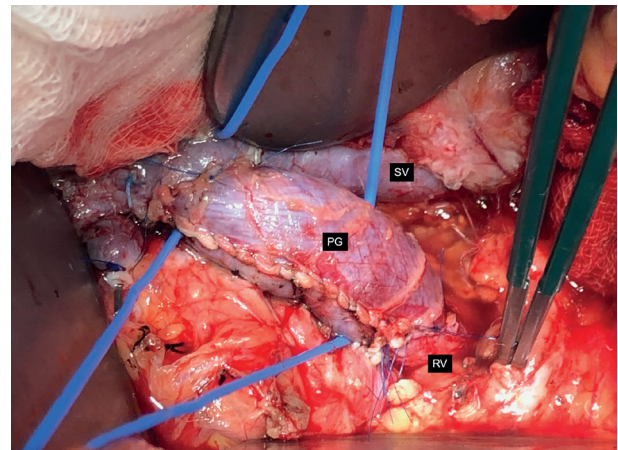


Fig 2. — Intra-operative picture: final aspect of the shunt. SV: Splenic Vein, PG: Peritoneal vascular Graft, RV: Renal Vein.

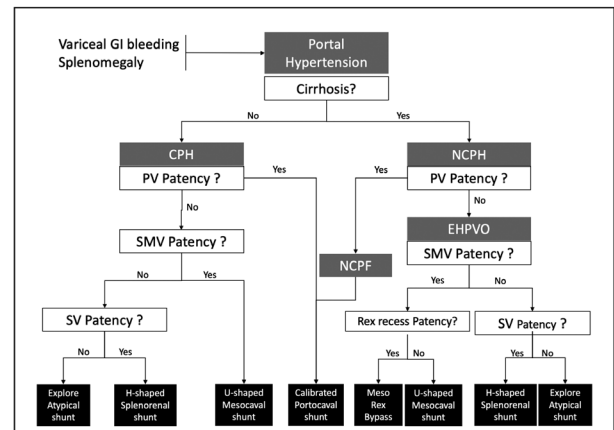


Fig 3. — Decision-making Tree for surgical shunt-only management of symptomatic Portal Hypertension (Exclusion of interventional-radiology, Sugiura-type and transplantation procedures). Atypical shunts are bypass procedures between the low-pressure vena cava system and a varicose vein or a high-pressure vascular branch (gonado-mesenteric shunt, cavernoma-caval shunt,...) GI: Gastro-Intestinal, CPH: Cirrhotic Portal Hypertension, NCPH: Non-Cirrhotic Portal Hypertension, PV: Portal Vein, EHPVO: Extra Hepatic Portal Vein Obstruction, NCPF: Non-Cirrhotic Portal Fibrosis, SMV: Superior Mesenteric Vein, SV: Splenic Vein.

refractory to endoscopic management is currently treated by TIPSS. Surgical options are still considered in EHPVO after failure of radiological repermeabilization and in some failures or contraindications of TIPSS. The patency of the spleno-mesenteric confluence would guide towards a SRS or, if applicable, a calibrated mesocaval shunt. The application of these bypass surgeries has therefore turned out to be sporadic, but their accessibility and efficiency still make them essential in countries with reduced access to healthcare. This practice is all the more marked as it is integrated in regions where patients with cirrhosis do not benefit from an organ allocation system and where the availability of liver transplantation is very low. Pre-emptive surgical management of GI bleeding

secondary to portal hypertension should be considered as a putatively beneficial therapeutic option.

SRS is not applicable in all cases, but its localization allows to avoid the dissection of a possible pedicular cavernoma. It also requires patency of the spleno-mesenteric confluence in case of EHPVO with extra gastroesophageal haemorrhage. We described our decision-making tree for patients referred for shunt surgery in figure 3.

Dissection and mobilization of the splenic vein in relation to the pancreatic relief may be difficult: the vein is at high pressure, sometimes “molded” by the pancreatic parenchyma, and has numerous short and fragile pancreatic drainage collaterals. Performing an H-shaped shunt with anastomosis and lateral clamping of this splenic vein limits dissection and makes the procedure easier than a distal SRS (Warren type) or direct lateral shunt. Traction on the inferior mesenteric vein also facilitates this lateral clamping at the level of the inferior spleno-mesenteric junction.

The use of fresh single layer autologous peritoneum as a vascular graft constitutes today a well-established technique. A French team has standardized the use of the Dokmak patch in partial or complete portal vein reconstructions during pancreatic surgery (4). We had also described its use in the form of cylindrical reconstruction as a vena cava substitute after multivisceral resection (5). Peritoneum is a mesothelium that has endothelializing properties. It has the advantage of being available in all circumstances, in all regions of the world whatever the healthcare conditions. It does not require specific logistics for the preservation of cadaveric vascular grafts. The available surface area makes it possible to extend the per-operative requirements that are sometimes difficult to reconcile with an autologous jugular, saphenous or deep femoral graft. Finally, compared to synthetic grafts, it is resistant to infection and available at zero cost.

Conclusion

We report the first H-shaped SRS performed by interposing a segment of rolled peritoneum as a vascular graft between the splenic and renal veins. Surgical management was uncomplicated, and the graft remains

patent with no GI bleeding event 24 months after surgery. This technique is applicable in all socio-economic contexts in contrast to radiological and endoscopic options and does not require the use of more expensive allogenic or synthetic grafts.

Acknowledgements

The authors thank Pierre Coubeau, also known as FSTN (<http://www.pierrecoubeau.com>), for his invaluable graphic contribution.

Funding

No grants and financial support.

Ethical approval

Written informed consent from patient was obtained.

Competing interest

No benefit in any form have been received or will be received from a commercial party related directly or indirectly to the subject of this article. All authors have seen, approved, and agreed with the contents of the manuscript. All authors are responsible for the accuracy of the manuscript.

References

1. GARCIA-TSAO G, SANYAL AJ, GRACE ND, *et al* (2007) The Practice Guidelines Committee of the American Association of the Study of Liver Diseases, The Practice Parameters Committee of the American College of Gastroenterology. Prevention and management of gastroesophageal varices and variceal hemorrhage in cirrhosis. *Hepatology*, **46**(3): 922-38.
2. LABERGE J, RING E, GORDON R, *et al* (1993) Creation of transjugular intrahepatic portosystemic shunts with the wall stent endoprosthesis: results in 100 patients. *Radiology*, **187**(2): 413-20.
3. SIMONETTI R, PERRICONE G, ROBBINS H, *et al* (2020) Portosystemic shunts versus endoscopic intervention with or without medical treatment for prevention of rebleeding in people with cirrhosis. *Cochrane Database of Systematic Reviews*, Issue **10**. Art. No.: CD000553.
4. DOKMAK S, AUSSILHOU B, SAUVANET A, *et al* (2015) Parietal Peritoneum as an Autologous Substitute for Venous Reconstruction in Hepato-pancreatobiliary Surgery. *Ann of Surg*, **262**(2):366-371(6).
5. COUBEAU L, RICO JURI J, CICCARELLI O, *et al* (2017) The Use of Autologous Peritoneum for Complete Caval Replacement Following Resection of Major Intra-abdominal Malignancies. *World J Surg.*, **41**:(1005-1011).