

Cholestasis in a cancer patient: think about the unicorn

G. Rasschaert^{1,2}, T. Seerden¹, M. van den Broek¹

(1) Department of Gastroenterology and Hepatology, Amphia Ziekenhuis, Breda, Noord-Brabant, The Netherlands; (2) Department of Gastroenterology and Hepatology, Universitair Ziekenhuis Brussel, Vrije Universiteit Brussel, Brussels, Belgium.

A 76-year-old male was referred for ongoing cholestasis of unclear origin. He had a stage IIIA non-small-cell lung carcinoma, treated for six months with adjuvant durvalumab after initial treatment with chemoradiotherapy. Durvalumab was halted three months ago after achieving stable disease for four consecutive months. Cholestasis was moderate with alkaline phosphatase (ALP) 5 x upper limit of normal (ULN), gamma-glutamyltransferase (GGT) 21 x ULN and normal bilirubin. There was one single episode of spontaneously transient postprandial abdominal pain a couple weeks before, besides absence of fever and pruritus. Viral serology and an auto-immune panel were negative, IgG4 was low. Computed tomography (CT) evaluation during his oncological follow up is shown in Figure 1. Relevant findings of an endosonographic (EUS) evaluation are shown in Figure 2.

What is the diagnosis?

The CT image shows a thrombosis in the left branch of the portal vein. The EUS image discloses cholecystolithiasis without signs of choledocholithiasis. More important, a slim inner diameter (3.3 mm) of the common bile duct is seen, while the wall is thickened along its entire trajectory, in continuation with the cystic duct and gallbladder wall. This could be seen in IgG4-related sclerosing cholangitis (IgG4-SC). However no other arguments were in favor. In light with the recent

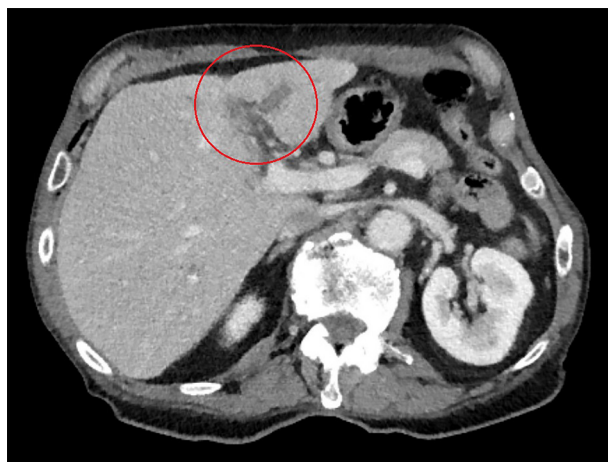

Figure 1. — Computed tomography disclosing a thrombosis in the left branch of the portal vein.

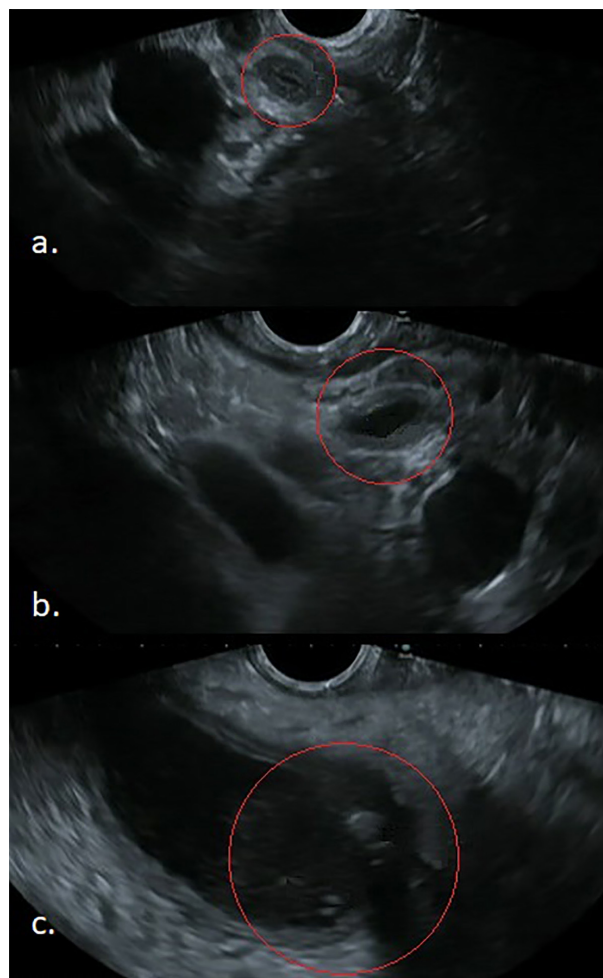


Figure 2. — Endosonography findings. Panel a. and b. show a common bile duct with a normal inner diameter of maximum 3.5mm, while its wall is thickened along its whole trajectory and in continuation with the ductus cysticus. There is no observed choledocholithiasis. Pannel c. illustrates the thickened gallbladder wall next to minimal cholecystolithiasis with observed umbra behind it.

treatment with durvalumab, a diagnosis of immune checkpoint inhibitor (ICI) related cholangitis was assumed and immune suppressive therapy by means

Correspondence to: Gertjan Rasschaert, MD, Universitair Ziekenhuis Brussel, Laarbeeklaan 101, 1090 Brussels, Belgium. Phone: +32473569814. Email: gertjan.rasschaert@uzbrussel.be

Submission date: 14/07/2022
Acceptance date: 26/07/2022

of methylprednisolone 40mg was started. Cholestasis subsided progressively in the following weeks.

Liver injury is a relatively common immune-related adverse event (irAE) (3-9%) (1). However ICI-related cholangitis is very rare, many aspects of the pathogenesis, diagnosis and treatment remain unclear. Time of onset varies from 1 to 11 months of ICI treatment. Most cases are related to PD-1 antibodies, however there are scarce reports with PDL-1 (durvalumab) and CTLA-4 blockers. Clinical presentation varies from asymptomatic to classic acute cholangitis features. Biochemically there is a cholestatic predominance (peak ALP 12-26 x ULN, GGT 6-44 x ULN). Imaging studies suggest two main patterns: primary sclerosing cholangitis-like ('PSC-like') and 'IgG4-SC-like'. EUS proves valuable in diagnosis and as predictive factor. In general irAEs are initially handled by interrupting ICI treatment, and eventually treated with steroids possibly combined with immunosuppressive therapy. There is no consensus for ICI-related cholangitis because of the lack of data. However the 'PSC-like'

subtype seems to respond less favorable. All four fatal cases described in literature were 'PSC-like'. The role of biliary drainage, EUS-FNA/FNB and per oral cholangioscopy is less clear at the moment (2).

Funding

None

Conflict of interest

The authors declare no competing interests.

References

1. SUZMAN DL, PELOSOF L, ROSENBERG A, AVIGAN MI. Hepatotoxicity of immune checkpoint inhibitors: An evolving picture of risk associated with a vital class of immunotherapy agents. *Liver Int.* 2018, **38**(6): 976-87.
2. NAKANO R, SHIOMI H, FUJIWARA A, YOSHIHARA K, YOSHIOKA R, KAWATA S et al. Clinical Characteristics of ICI-related Pancreatitis and Cholangitis Including Radiographic and Endoscopic Findings. *Healthcare (Basel)* 2022, **10**(5), 763-77.