

Endoscopic ultrasound-guided biliary drainage for distal malignant biliary obstruction: a prospective 3-year multicenter Egyptian study

K.M. Ragab¹, M. Abdel-Hameed¹, M. Gouda¹, H. Katamish¹, A. Madkour², H. Atalla³, H. Hamed⁴, G.E. Shiha³, O. Abdallah³, R.H. Agwa³, E. Ghoneem³

(1) Hepatology and gastroenterology department, Theodor Bilharz Research Institute, Egypt; (2) Tropical medicine, Helwan university, Egypt; (3) Hepatology, Gastroenterology, Internal medicine department, Mansoura university, Egypt; (4) Gastroenterology surgery unit, General surgery department, Faculty of medicine, Mansoura University, Egypt.

Abstract

Background/Aim: Malignant biliary obstruction (MBO) is often diagnosed at late stages with mostly unresectable lesions. Recently, EUS-guided biliary drainage (EUS-BD) has gained wide acceptance and appears to be a feasible and safe backup option after ERCP failure in such patients. Herein, we aimed to represent a 3-year multi-center Egyptian experience in the application of this challenging procedure for distal MBO as a salvage technique after failed ERCP.

Patients and methods: This was a prospective multi-center study of patients underwent EUS-BD for distal MBO in the duration between December 2018 and December 2021, after ERCP failure.

Results: Ninety-one patients (59 males, median age: 61 years) were included in the study. EUS-guided extrahepatic approach including choledcho-duodenostomy (CDS) was done for 48 patients (52.8%), followed by choledcho-antrostomy (CAS) in 4 patients (4.4%). The intrahepatic approach included hepaticogastrostomy (HGS) for 35 patients (38.5%) and antegrade stenting (AG) stenting in 2 patients (2.2%), while Rendezvous (RV) approach was performed in 2 patients (2.2%). Technical and Clinical success were achieved in the majority of cases; 93.4% and 94.1% respectively. Adverse events occurred in 13.2% of patients which were mostly mild (8.2%) to moderate (2.4%). Only one patient died within 48h after the procedure with progression of preceding sepsis and organ failure.

Conclusion: EUS-BD is a feasible option, even in developing countries, after a failed ERCP, and it is a relatively safe option in patients with MBO once experienced team and resources were present. Majority of cases in our study have achieved technical and clinical success with relatively low incidence of adverse events. (*Acta gastroenterol. belg.*, 2023, 86, 26-35).

Keywords: EUS BD, distal CBD malignant stricture, ERCP.

Introduction

Biliary stricture is defined as a fixed focal narrowing involving any segment of the biliary tree, associated with proximal dilatation and clinical manifestations of obstructive jaundice (1).

Biliary strictures had numerous benign and malignant causes.

Most patients diagnosed with malignant obstructive jaundice present unfortunately at later stages with mostly un-resectable lesions requiring only palliative measures (4). Biliary drainage (BD) via endoscopic or percutaneous route is the ideal management option to relieve obstruction in such patients (5). In terms regarding better quality of life; the endoscopic approach is preferred for most patients, whereas the percutaneous route is reserved after the failure of the endoscopic approach (4).

Over the past decades, endoscopic retrograde cholangiopancreatography (ERCP) has proven to be the gold standard approach as a therapeutic device for biliary obstruction in both benign and malignant strictures (6-8). Nevertheless, failure is encountered in about 5-10% of cases (9). This may be due to anatomical abnormalities, periampullary pathology (tumor destructing the papilla or duodenal stenosis), or altered intra-abdominal anatomy (previous abdominal surgeries altering normal anatomies like gastrectomy and malabsorptive bariatric procedures) (9).

Endoscopic ultrasound (EUS) has developed as a diagnostic modality but rapidly gained a role for a variety of therapeutic applications (10,11). It allows real-time visualization of the surrounding structures (12). In addition, it could create an anastomosis between the biliary and alimentary lumen to allow biliary drainage (13,14). This could be a valid option after ERCP failure (15,16).

Since it was first described by Giovannini et al, (17) EUS-BD is rapidly growing and now is generally preferred over PTBD in high volume centers for multiple reasons; being less invasive, more physiological biliary draining treatment and associated with better quality of life with less need for a long-term external body drain, improves nutrition absorption from the gastrointestinal tract, and minimizes excessive electrolyte loss (18) has a lower re-intervention rate. Moreover, if ERCP fails, it can be accomplished safely in the same endoscopic session reducing the cost of repeated procedures (19). In addition, when conducted by experts, EUS-BD has a high technical and clinical success rate (over 90%); however, there was worry about the initial reported adverse event rate, which was attributed to variables such as the learning curve, and the lack of dedicated devices (20).

Herein, we represent a multi-center Egyptian experience in the application of EUS in biliary drainage (EUS-BD) in cases diagnosed with malignant obstructive jaundice as a salvage technique after failed ERCP.

Correspondence to: K.M. Ragab, Consultant of gastroenterology and endoscopy, Theodor Bilharz Research Institute, Giza, Egypt. Phone: 00201009646294. Email: khalidmohamedragab@yahoo.com

Submission date: 25/06/2022

Acceptance date: 11/01/2023

Patients and methods

Patients and study design

In the duration between December 2018 and December 2021, patients with history of malignant biliary obstruction (MBO) and failed ERCP, either in relation to technical difficulty or an in-accessible papilla, were enrolled for EUS-BD. This study was conducted at three tertiary medical centers; Specialized Medical Hospital at Mansoura University, Theodore Bilharz research institute, and the Egyptian Liver Hospital. Exclusion criteria included patients who underwent primary EUS-BD, those with high up biliary obstruction, benign biliary strictures, un-corrected coagulopathy and severe comorbidity impeding the endoscopic procedure. Patients' data were retrieved from a prospectively maintained database. Data included patients' baseline demographics, cause of obstruction, site and features of malignant stricture, cause of ERCP failure, pre-procedural CBD diameter, pre- and post- procedural bilirubin levels, type of biliary drainage approach, the need for dilatation and used device, type of the stent, procedure duration, technical success, clinical success, endoscopic adverse events, duration of hospitalization, need for stent repositioning, and stent durability. Follow up laboratory investigations and trans-abdominal ultrasound were done routinely during the admission. Follow-up for included patients was done weekly within the first month then monthly after the procedure through outpatient clinic visits in the previously mentioned centers.

The study protocol was reviewed and approved by the institutional review board of Egyptian liver hospital. The study was conducted in accordance with the Declaration of Helsinki and the consolidated Good Clinical Practice guidelines. All authors had access to the study data, and they all reviewed and approved the final manuscript. Informed written consent was obtained from all participants after detailed explanations of the approach, benefits, and possible complications of the planned procedure.

Treatment strategy, endoscopic procedure and its evaluation

Endoscopic procedures

All procedures were done by experts in diagnostic and interventional EUS.

In all procedures we used one of two echoendoscopes; Pentax linear echoendoscope EG-3870UTK (PENTAX Medical, Tokyo, Japan), with a Hitachi-Aviu processor (Hitachi, Tokyo, Japan) and Fujifilm EG-580UT Curved Linear Endoscopic Ultrasound scope with SU-1 (Fujifilm Global, Tokyo, Japan).

EUS-guided interventional approaches included either extrahepatic (choledcho-duodenostomy (CDS) or choledcho-antrostomy (CAS) or intrahepatic (Hepatico-

gastrostomy (HGS), Rendez-vous (RV) and Antegrade stenting (AG)) approaches according to the level of the obstruction, state of the duodenum, and the experience of the endoscopist.

In all procedures we followed steps in order using the available instruments. Used instruments included a 19G EUS-FNA needle (Echotip needle, Wilson-Cook Medical Inc., Winston-Salem, USA, or EXPECT needle Boston Scientific, Natick, MA, USA), 0.035 or 0.025 ERCP guidewire (Jagwire; Boston-Scientific), 6 French cystotome (Cysto Gastro Set; Endo-flex, GmbH, Voerde, Germany), Souhendra dilator (Wilson-Cook Medical) or mechanical dilator EZ Dilator (Zeon Medical Co, Tokyo, Japan). Different types of stents (Table 3) were used depending on the type of intervention and length of the fistulous tract. Used stents varied in length (6, 8, or 10 cm), and coverage (partially, half to half, 1/3 uncovered: 2/3 covered or fully covered). Stents included: partially covered (Wallflex, Boston Scientific, Natick, MA, USA; Hanaro stent, M.I. Tech, Seoul, Korea), Fully covered (Evolution® Biliary Stent Wilson-Cook Medical, Winston-Salem, NC, USA), Half to Half stent (Hanaro) and Hepato-gastric stent (Hanaro stent BPD® MI Tech, Seoul, Korea).

The extrahepatic approach was selected for cases with previous failure of deep cannulation due to an ampullary neoplasm, infiltrating pancreatic cancer, or duodenal stenosis. Either CDS or CAS was performed in such patients. The endoscope was advanced to the duodenal bulb or gastric antrum till identification of the dilated CBD with the scope in the long position and its tip directed towards the hilum. After identification of the proper puncture site guided by Doppler Ultrasound with exclusion of intervening blood vessels, a 19-G needle was inserted into the CBD, with subsequent confirmatory aspiration of the cumulated bile. At this step, double penetration of the duodenal wall generally should be avoided through either identification of the single muscle layer, intraluminal instillation of water, and the use of forward-view echoendoscope if available. Thereafter, opacification of biliary tree using contrast material followed by insertion of a 0.035- or 0.025-inch guidewire through the needle, with negotiation of the wire towards the intrahepatic biliary radicles (IHBRs). A fistulous tract was then created between the CBD and either duodenum or gastric antrum using a cystotome (6-8.5 Fr). Finally, stent insertion was done either under direct endoscopic vision or with the point of no-return inside the working channel at the last step of stent deployment leaving at least 2 cm of the stent intraluminal (Fig. 2.)

Regarding the intrahepatic approach, it was applied in cases in whom the duodenal papilla was not accessible (due to gastric outlet obstruction) or when altered anatomy was encountered. The tip of the scope was applied against the lesser curvature till identification of dilated left hepatic duct (segments II or III). The following steps were applied the same as extrahepatic approach with deployment of the stent through the fistulous tract

Table 1. — Classification of the severity of endoscopic adverse events according to the lexicon by American Society for Gastrointestinal Endoscopy [24].

Grade	Definition
Mild	<ul style="list-style-type: none"> - The procedure was aborted due to an adverse event. - Events requiring medical consultation after the procedure or extended hospital admission (≤ 3 nights).
Moderate	<ul style="list-style-type: none"> - Unplanned ventilatory support. - Extended ward (4-10 nights) or ICU (1 night) admission. - The need for blood transfusion. - Events mandating interventional radiology or repeat endoscopy.
Severe	<ul style="list-style-type: none"> - Extended ward (>10 nights) or ICU (>1 night) admission. Events requiring surgical intervention. - Residual permanent disability.
Fatal	<ul style="list-style-type: none"> - Death

Table 2. — Baseline characteristics and cause of biliary obstruction

Variable	n (%) / Median (IQR)
Age (years)	61 (55-69)
Sex	
Males	59 (64.8%)
Females	32 (35.2%)
Preprocedural total bilirubin (mg/dl)	17 (12-22)
Preprocedural direct bilirubin (mg/dl)	13.6 (9.43-17.5)
Preprocedural CBD diameter (mm)	16 (15-18)
Cause of biliary obstruction	
Advanced pancreatic/ ampullary tumor with no duodenal obstruction	58 (63.7%)
Advanced pancreatic/ ampullary tumor with duodenal obstruction	17 (18.7%)
Altered anatomy (with tumor recurrence post-whipple operation)	7 (7.7%)
Cholangiocarcinoma (Mid and Distal CBD)	5 (5.5%)
Undifferentiated CBD malignancy	4 (4.4%)

Table 3. — Technical details

Variable	N (%) / Median (IQR)
Type of EUS-BD procedure	
Choledochal- Duodenostomy	48 (52.7%)
Hepatico- Gastrostomy	35 (38.5%)
Antegrade stenting	2 (2.2%)
Rendez-vous	2 (2.2%)
Choledochal- antrostomy	4 (4.4%)
Liver segment punctured in Intrahepatic approach	
Segment III	26 (76.5%)
Segment II	8 (23.5%)
Procedure duration (minutes)	20 (15-27)
Dilatation	
Cystotome 6 Fr	81 (89.0%)
Cystotome 8.5 Fr	7 (7.7%)
Mechanical dilatation	3 (3.3%)
Type of used stent	
Fully covered	4 (4.7%)
Partially covered	50 (58.8%)
Half to half	18 (21.2%)
Metallic stent 1/3 uncovered 2/3 covered	12 (14.1%)
Single pectail Plastic stent (8.5 Fr*12cm)	1 (1.2%)
Length of used stent	
6 cm	42 (49.4%)
8 cm	14 (16.5%)
10 cm	29 (34.1%)

into gastric lumen leaving more than 3cm of the distal end intragastric (HGS). Fistula creation was carried out using either cystotome or mechanical dilator using EZ or Souhendra dilators (Fig 3).

The Rendez-vous (RV) or Antegrade (AG) stenting approaches were performed in cases with juxta-papillary diverticula, ampullary tumors or patients with surgically altered anatomy. Under EUS-guidance, the intra-hepatic biliary tree (segment II) was accessed using the 19-G needle, and a 0.025 inch guidewire was passed through the biliary tree into the duodenum. Subsequently, in case of RV technique, the EUS was withdrawn leaving the guidewire in place, and then the ERCP was inserted parallel to the guidewire. We then either used a snare to catch the guidewire end at the duodenum or directly cannulated the CBD beside the guidewire, and then a stent was inserted via the conventional ERCP procedure. In the AG approach; after the guidewire has reached the duodenal lumen, stent was deployed over the guidewire in an antegrade fashion under both fluoroscopy and EUS-guidance into the intestinal lumen.

Pre-procedural intravenous antibiotic (3rd generation cephalosporins or quinolones) was administered and continued for 3-5 days post-procedural.

Outcomes

The primary outcome of the study included technical and clinical success of EUS-BD. Technical success was defined as the successful placement of the stent at the end of the procedure in proper position; with one end in the biliary tree and the other in the alimentary tract. Clinical success was defined as a 50 % or more decrease

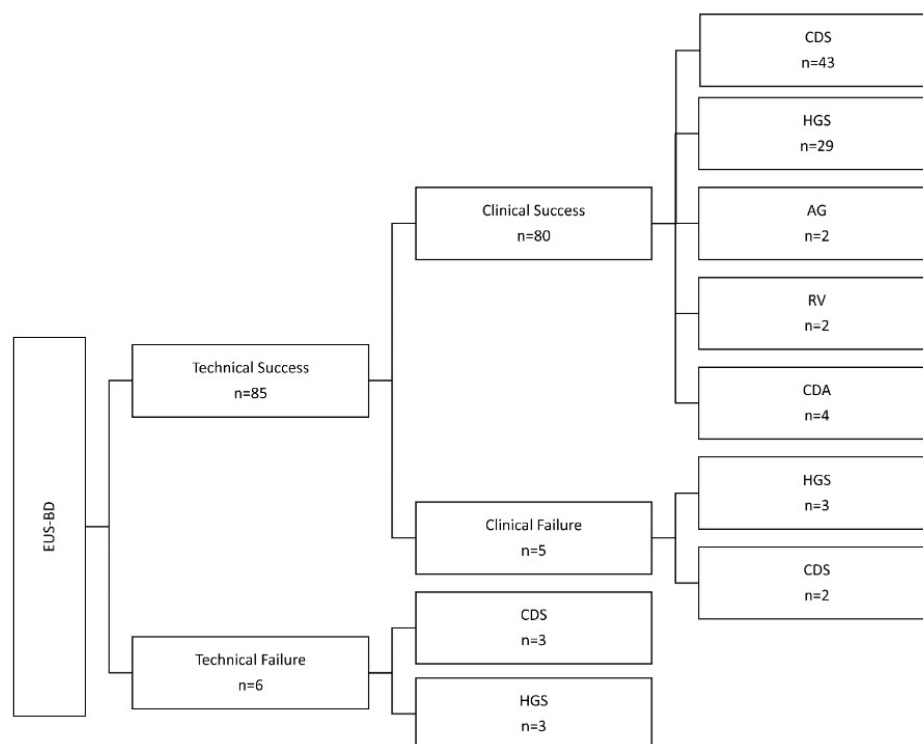


Fig. 1.

in serum total bilirubin 2 weeks after the procedure or to less than 3mg/dl after one month (21,22). Secondary outcomes included the procedural duration, occurrence of adverse events, 7-days mortality and recurrent biliary obstruction.

Adverse Events

Definition and classification of endoscopic adverse events (AEs) were adopted from the lexicon by American Society for Gastrointestinal Endoscopy (20). AE was defined as an event causing interruption of the procedure and/or requiring medical consultation, hospitalization, endoscopic or surgical intervention. Table 1 details the classification of the severity of AEs based on the required management. When there was more than one AE, the most serious was the one to be counted.

Statistical analysis

Categorical variables were expressed as group percentages and were compared for independent samples using Chi-square test. Continuous data were presented as medians (interquartile range, IQR) and were compared using Wilcoxon's signed ranks test. The statistical significance level was set at <0.05. Statistical analyses were performed using SPSS version 23 (Chicago, IL).

Results

In the study duration, ninety-one patients were included; 59 males (64.8%). A flowchart of the EUS-BD

procedure is summarized in figure 1. Their median age was 61 years, ranging from 25 to 80 years. Advanced pancreatic/ampullary tumor without duodenal obstruction was the commonest cause of biliary obstruction (63.7%). Patients' baseline characteristics and cause of obstruction are summarized in Table 2.

All cases had a previous trial of failed ERCP. The most common cause of failure was due to inability to achieve deep cannulation in 55 patients (60.4%), followed by duodenal infiltration in 13 patients (16.5%), gastric outlet obstruction in 15 patients (14.3%), and altered anatomy (post-Whipple operation) in 8 patients (8.8%).

Regarding technical details, extrahepatic approach including CDS was done for 48 patients (52.8%), followed by CAS in 4 patients (4.4%). The intrahepatic approach included HGS for 35 patients (38.5%) and AG stenting in 2 patients (2.2%), while RV approach was performed in 2 patients (2.2%). Table 3 and 4 summarized the details of EUS-BD techniques.

Technical success was attained in all patients attempted EUS-BD apart from 6 patients (6.6%) (3 in both CDS and HGS groups). Technical CDS failure was encountered in three cases in whom the guide wire was slipped accidentally after cystotome dilatation of the fistulous tract with subsequent collapse of the CBD and failed re-puncturing trials. These cases were treated by percutaneous biliary drainage (PTBD) with two cases of them developed sub-hepatic collection and needed peritoneal tube drainage. The other three cases of technical failure were in the HGS group. The cause of technical failure in one case of them was similarly slippage of the guidewire after contrast enhancement of

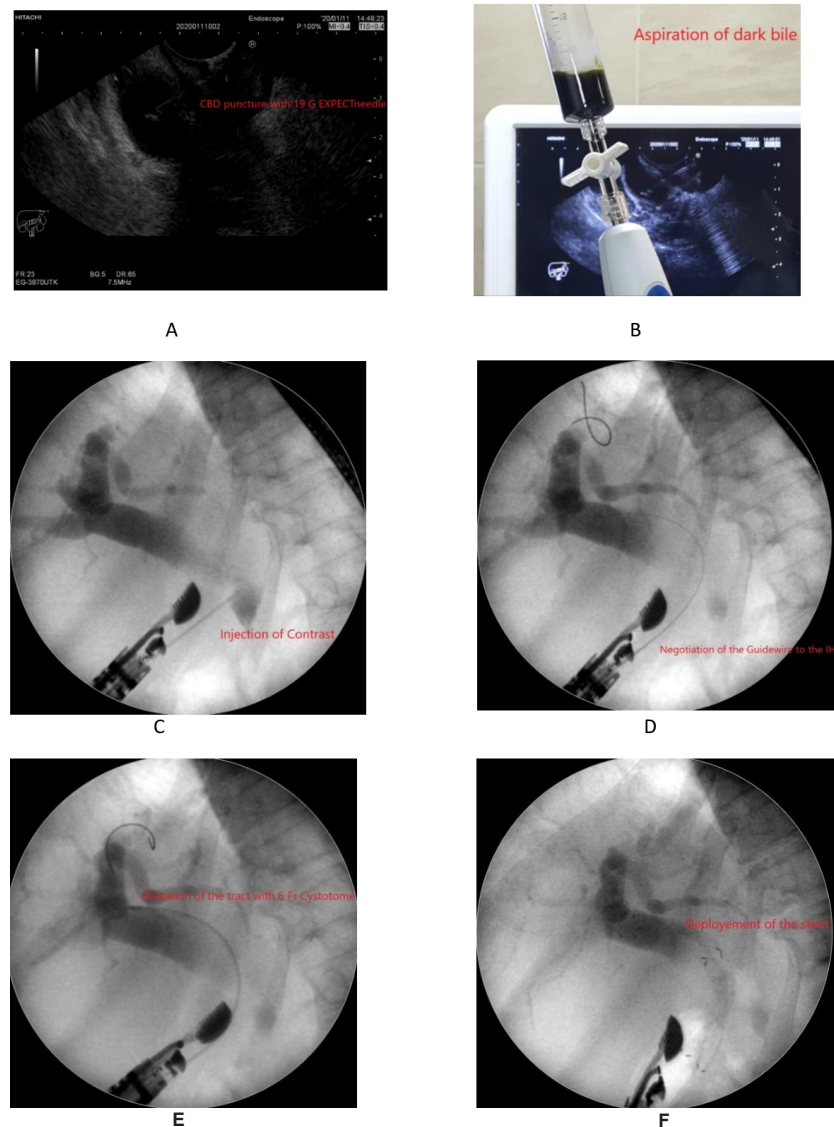


Fig. 2. — EUS guided CDS; A: EUS guided puncture of dilated CBD with 19G needle; B: Bile aspiration; C: Opacification of the CBD and biliary system under fluoroscopic view; D: Negotiation of the guidewire to pass centrally to IHBRs; E: Creation of the tract using 6Fr cystotome; F: Deployment of biliary SEMS.

biliary tree with subsequent failure to re-access it. On the other hand, inability to puncture the intrahepatic biliary radicles (IHBRs) was faced in the other 2 cases; in the context of multiple hepatic focal lesions with minimally dilated IHBRs in one patient and moderate ascites in the other.

The clinical outcome of EUS-BD is outlined in (Table 5). Clinical success was achieved in the majority of cases ((n=80/85) 94.1%). The performed interventions were associated with a significant decrease of both total and direct bilirubin values (Table 6) compared to their baseline levels. Most patients were referred accordingly for oncological management and chemotherapy was started successfully for 68 patients (80%) of our cohort. Nonetheless, clinically five cases (3 HGS and 2 CDS patients) failed to achieve the optimum decrease in bilirubin level. Yet, the stent patency was confirmed with

the presence of pneumobilia on follow up imaging. The clinical failure in those patients was related mostly to the preceding disease progression, prolonged cholestasis and or preceding sepsis.

Overall adverse events (AEs) were encountered in 11 patients (13.2) of our study cohort (Table 5). AEs ranged from mild events in 7 patients (8.2%) including post-procedural mild abdominal pain and self-limited fever, moderate (two cases, 2.4%) to severe (one case, 1.2%) events with biliary peritonitis occurrence in 3 patients after HGS with the requirement of admission in the intensive care unit. So far, fatal outcome was encountered in one patient in the HGS group, died within 48h after the procedure. On the other hand, events related to endoscopic procedure included stent mal-positioning in 7 patients. Stent mal-deployment (intraluminal part of the stent <2 cm) occurred during the procedure in four of

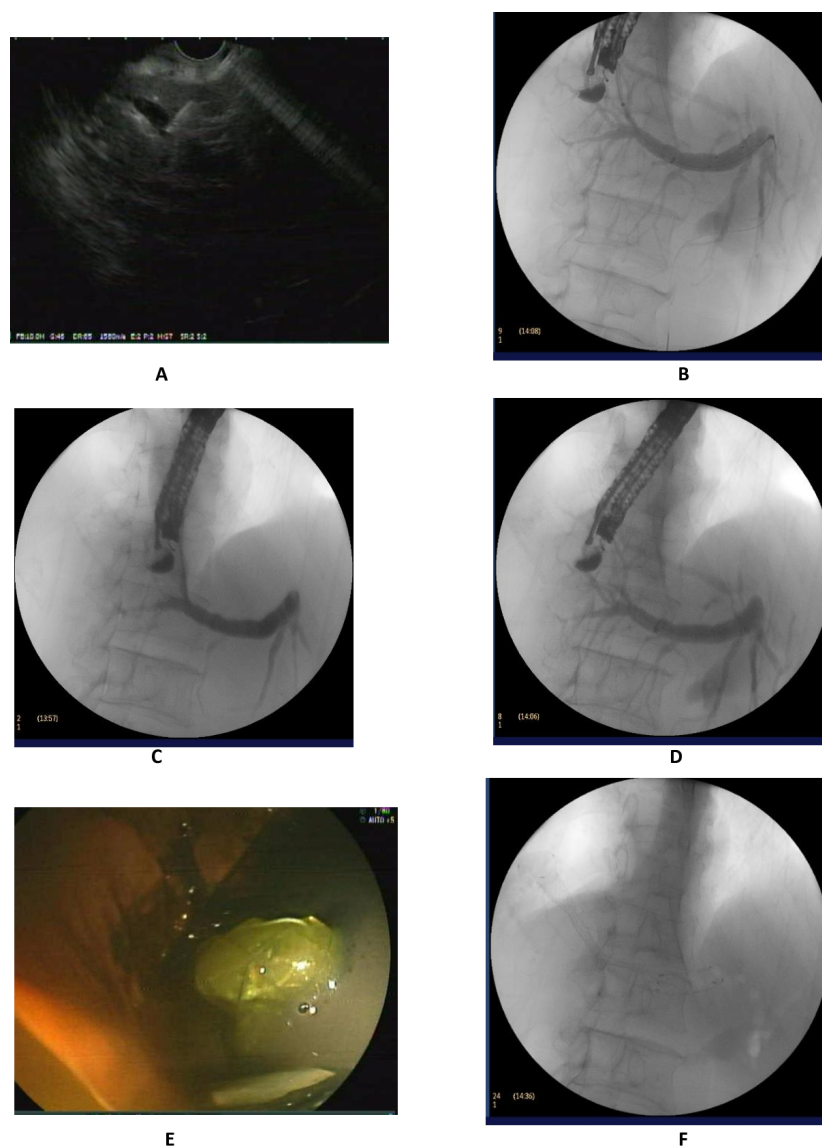


Fig. 3. — EUS guided HGS; A: EUS guided puncture of dilated LHD with 19G needle; B: Opacification of the BIII and left biliary system under fluoroscopic view; C: Negotiation of the guidewire to pass centrally; D: Creation of the tract using 6Fr cystotome; E and F: Deployment of HGS stent, Hanarostent BPD, under endoscopic and fluoroscopic view.

them (4.7%) with the need for stent repositioning using a snare device or foreign body forceps.

When comparing CDS with HGS cases, no significant difference was noted as regards the number or severity of endoscopic adverse events. Also, clinical and technical success rates were also comparable between the two groups ($p > 0.05$). (Table 7) illustrates these data.

Discussion

In our study, we demonstrate the experience of EUS-BD for MBO in three Egyptian tertiary centers. Considerably, in such a developing country in the Middle East with a relatively low income, this advanced

dedicated technique faces many challenges particularly the high costs, less-availability of needed accessories (namely rotatable guidewires, double lumen cannulas, dedicated dilators and modified anti-migratory stents) and the scarcity of a highly experienced endoscopic teams for this procedure. In comparison to previously published Egyptian study (23), this one continues to be the first prospective, three-year study with such a large number of patients, representing a comprehensive real-life experience of this largely non-well established procedure in Egypt with focusing on adverse events and faced challenges.

Technical and clinical success rates were established in 93.4% and 94.1% of included patients respectively. In

Table 4. — Comparison between different types of drainage procedures

Total cases of technical success n=85	CDS n=45	HGS n=32	AG n=2	RV n=2	CDA n=4
Indication for EUS-BD					
- Failed deep cannulation	36 (80)	10 (31.3)	2 (100)	2 (100)	-
- Gastric outlet obstruction	-	8 (25.0)	-	-	3 (75)
- Duodenal infiltration	9 (20)	7 (21.9)	-	-	1 (25)
- Surgically Altered anatomy	-	7 (21.9)	-	-	-
Cause of biliary obstruction					
- Advanced pancreatic/ ampullary tumor with no duodenal obstruction	40 (88.9)	9 (28.1)	2 (100)	2 (100)	1 (25)
- Advanced pancreatic/ ampullary tumor with duodenal obstruction	3 (6.7)	11 (34.4)	-	-	3 (75)
- Altered anatomy	-	6 (18.8)	-	-	-
- Cholangiocarcinoma (Mid and Distal CBD)	-	5 (15.6)	-	-	-
- Undifferentiated CBD malignancy	2 (4.4)	1 (3.1)	-	-	-
Type of stent used					
- Fully covered	2 (4.4%)	2 (6.3)	-	-	-
- Partially covered	39 (86.6)	5 (15.6)	2 (100)	1 (50)	4 (100)
- Half to half	4 (8.9)	13 (40.6)	-	-	-
- Metallic stent 1/3 uncovered 2/3 covered	-	12 (37.5)	-	-	-
- Single pigtail Plastic stent (8.5 Fr*12cm)	-	-	-	1 (50)	-
Length of used stent					
- 6 cm	38 (84.4)	-	2 (100)	1 (50)	1 (25)
- 8 cm	7 (15.6)	5 (15.6)	-	-	3 (75)
- 10 cm	-	27 (84.4)	-	1 (50)	-
Pre-procedural total bilirubin (mg/dl) median (IQR)	16.57 (12-21.6)	16.4 (11.8-22.6)	12.0-33.7	6.0-18.0	22.0 (18.8-24.5)
10 days Post-procedural total bilirubin (mg/dl)	4.5 (3.0-6.3)	4.3 (3.0-8.0)	3.0-11.3	2.0-4.0	4.5 (2.9-8.87)
Duration minutes: median (IQR)	18 (15-25)	20 (15-30)	35-40	40-45	21.5 (14-23.75)

Notes: Data are N (%) or median IQR.

the literature, technical success rates of EUS-BD ranged from 90.2 % to 100 %, while clinical success rates ranged from 84.4 % to 98.2 % (24).

EUS-BD techniques involved in this study were intra- and extra-hepatic approaches, rendez-vous and antegrade (AG) stenting procedures. To date, the best technique for biliary drainage is still debatable and, in most cases, depends on the anatomical consideration and endoscopist's judgment. In a systematic review and meta-analysis by Uemura et al., 2018 including 10 studies with 434 patients (25), CDS and HGS were equally effective and safe with a high technical and clinical success rates for both. Rates of technical success for CDS and HGS were 94.1% and 93.7%, respectively, while clinical success rates were 88.5% and 84.5% for CDS and HGS respectively. Moreover, in this meta-analysis, rates of AE were comparable between both techniques with slight non-significant increase in cholangitis in CDS cases. Regarding time of the procedure, only CDS was slightly faster by 2 minutes than HGS at pooled analysis. Coping with this data, our results did not reveal any significant difference between CDS and HGS, regarding efficacy and safety.

Technical and clinical success rates in CDS were established in 93.8% and 95.6% respectively. In HGS group, technical and clinical success were achieved in 91.4% and 90.6% respectively.

Regarding procedure time, there was no significant difference between CDS and HGS procedures.

Table 5. — Outcome of EUS-guided biliary drainage

Outcome	n (%) / Median (IQR)
Technical success	
Success	85 (93.4%)
Failure	6 (6.6%)
Clinical success	
success	80 (94.1%)
Failure	5 (5.9%)
Adverse events	
No	74 (87.1%)
Mild	7 (8.2%)
Moderate	2 (2.4%)
Severe	1 (1.2%)
Fatal	1 (1.2%)
Stent mal-positioning	
During procedure	4 (4.7%)
After procedure	3 (3.5%)
Hospital stay (days)	2 (IQR: 1-2), (Range: 1-15)

Notes: Data are N (%) or Median (IQR).

Nonetheless, the median duration of CDS was 2 minutes less than HGS. A more recent meta-analysis by Li et al, (26) has supported that CDS was slightly faster and they recommended to limit the number of accessory changes during HGS to decrease the process duration.

Regarding AE, despite being variable, ranging from: self-limited pain, fever, pneumo-peritoneum to biliary peritonitis; the rate of AEs seems to be declining over time with increased experience and standardized approaches. In our study, AE rate was (13.2%) which is comparable

Table 6. — Serum bilirubin before and after intervention

Serum bilirubin (mg/dl)	Preprocedural	Postprocedural	Z value	P value
Total	16.8 (12-22)	4 (3-7.8)	-7.989	<0.001
Direct	13.5 (9.4-17.2)	2.7 (1.95-5)	-7.979	<0.001

Notes: Data are median (IQR). Test of significance is Wilcoxon's signed ranks test.

Table 7. — CDS versus HGS procedures

Item	CDS	HGS	Total	P value
Technical Success				
Yes	45 (93.8%)	32 (91.4%)	77 (92.8%)	0.693
No	3 (6.2%)	3 (8.6%)	6 (7.2%)	
Clinical Success				
Success	43 (95.6%)	29 (90.6%)	72 (93.5%)	0.749
no success	2 (4.4%)	3 (9.4%)	5 (6.5%)	
Adverse Events				
No	41 (91.1%)	26 (81.3%)	67 (87.0%)	0.218
Mild	4 (8.9%)	3 (9.4%)	7 (9.1%)	
Moderate	0 (0%)	2 (6.3%)	2 (2.6%)	
Severe	0 (0%)	1 (3.1%)	1(1.3%)	
Duration (minutes) Median (IQR)				
	18 (15-25)	20 (15-30)	77 (92.8%)	0.251

to previous studies, with overall risk in the literature for HGS as 19% (ranging from 0-35%) (27) and 13.6-20% in CDS (26). Most AE occurred in our study were mild (8.2), but unfortunately one fatal outcome was met in our study. This patient was referred to our hospital at a late stage of disease progression and obstruction-related sepsis which needed urgent relief through biliary drainage. Even though, after successful EUS-BD technically, patient condition worsened and a massive hematemesis occurred in the context of DIC. Thus, we claim that this major AE was related to the underlying disease progression not the procedure itself.

Likewise, we had two cases (2.4%) with moderate complication related to biliary peritonitis from post procedure stent migration just at the edge of the gastric wall (although sufficient intraluminal length was confirmed at the end of the procedure), they managed by metallic stent in stent deployment. Another patient had complete intra-peritoneal stent migration however a successful ERCP trial was carried out with deployment of biliary SEMS. This patient survived without any surgical intervention till lost follow-up after 2 months. The physiological antegrade drainage using the biliary SEMS in the CBD could be the major factor protecting against biliary peritonitis in this patient whom was unfit for surgery. The three cases were admitted into ICU (5 days in the first two and 10 days in the 3rd one).

Actually, all post-procedure migrated stent occurred in HGS group using partially covered self-expandable metal stents (PC-SEMS) 8cm in length (Wallflex, Boston Scientific, Natick, MA, USA). This could be related to

the high axial force and high shortening ratio of this stent that may reach up to 30% (28).

Despite the difference between both techniques did not reach significance, yet, the worst AE (intra-peritoneal stent migration) have occurred only in the HGS group. A recent study by Ochiai et al, tried to determine the risk factors for this serious AE and concluded that the likelihood of stent migration was enhanced when the distance between the stomach and liver at the puncture site was longer (29). Furthermore, aiming to prevent this fatal AE, Nakai et al. (30) have used a dedicated long partially covered metal stent with a flared portion at its gastric end for HGS in patients with MBO (type stent partially covered Boston scientific). Long-term results were favorable and even at recurrence of biliary obstruction, treatment was achieved in most cases through the same previously placed stent. Another modification in the HGS method was proposed by Mandai et al, (31) to limit free space between the liver and the gastric wall. They used also a long partially covered metal stent but tried to keep pressing the gastric wall (the intraperitoneal stent length) with the scope tip until the stent was deployed more than 1 cm inside the scope's working channel. Outcomes were encouraging achieving 100% technical success without any stent migration or dislocation even in patients with surgically altered anatomy. Similar studies (32,33) showed beneficial effect of this intra-channel technique. In our cohort, modifying stent position using accessories like snare in case of mal-deployed stent or deploying another SEMS inside the migrating one (Tandem stent placement (34)) were beneficial options. In the same

topic, the meta-analysis by Li et al, declared that EUS-HGS had higher early but not late AE (specifically stent dysfunction) than CDS, implying that EUS-CDS may be safer than HGS. They suggested that HGS should not be tried except after enough experience in the field of interventional EUS (26).

Furthermore, Stent mal-deployment (intraluminal part of the stent <2 cm) occurred during the procedure in four patients with stent repositioning using a snare device or foreign body forceps. In fact, these cases were done at the early phase of the study after which we decided to change the stent deployment maneuver to be deployed inside the working channel of the scope. Fortunately, these four cases had uneventful post-procedural follow-up.

So far, Rendez-vous, Antegrade stenting (AG) and choledcho-antrostomy (CAS) techniques were not included in the comparative analysis as they were represented by only few cases. On the other hand, we report four cases of CAS performed in our study with complete technical and clinical success despite the challenging position of the stent between gastric antrum, which has a high rate of peristaltic contractions, and CBD. Actually, the first case of CAS was done un-intentionally while trying to do CDS in patient with infiltrated duodenum; the scope was slipped from duodenal bulb into the antrum being in close proximity to a hugely dilated CBD which was easily punctured. The remarkable clinical success without early or late AE in this case encouraged us to try it on purpose in the next 3 cases of duodenal infiltration having a similar intimate relation between gastric antrum and CBD, which interestingly yielded similar outcomes. Revising literature revealed that this dedicated procedure was reported only twice, up to best of our knowledge, by Artifon et al. (35) and Itoi et al. (36), declaring its easier maneuver similarly to CDS with a more stable position for the echoendoscope, reducing the risk of losing the guidewire, and since biliary drainage is performed through the physiological antegrade bile flow. However, the risk of stent migration is still present and this procedure should be chosen after un-accessible HGS due to non-dilated bile radicles with duodenal infiltration and anti-migratory stents like LAMS may be the stent of choice in these cases.

Stents used in our study were all of the metal type apart from only one plastic stent. Nevertheless, the best stent type is still debatable with most data regarding long-term stent patency was exploited from ERCP studies. However, partially covered metal stents may be one of the best choices in EUS-BD; avoiding focal cholangitis from peripheral duct obstruction with long-term stable position using the uncovered part and particularly when longer stents are chosen (27). Another point for discussion is the use of plastic versus metal stents. Despite a dedicated single pigtail plastic stent was reported to be safe and effective for HGS in 23 cases by Umeda and Itoi et al. (37), in a recent worldwide multi-institutional survey among members of the International Society of EUS, Self-expandable metal

stents (SEMSs) were recommended over plastic ones by most endoscopists (38). In the randomized, multicenter trial by Schmidt et al, on 37 patients (39) stent patency and complication rates were compared between a winged type plastic stent and SEMS. In their study, the plastic stent group had a considerably higher rate of stent failure than the SEMS group within 8 weeks of insertion. Thus, we think that further future studies on large population may disclose this debate.

In conclusion, we tried in this study to prove that EUS-BD is a feasible option, even in developing countries, after a failed ERCP, and it is a relatively safe option in patients with MBO once experienced team and resources were present. Majority of cases in our study have achieved technical and clinical success with relatively low incidence of adverse events which were mostly mild to moderate. However only one patient died within 48h after the procedure owing to the progress of preceding sepsis and multi-organ failure. Adverse events are sometime non-avoidable, however, good pre-procedural preparation, adopting solid criteria for patient selection, clear backup plans and multidisciplinary team discussion and cooperation are the basis for best management of these events.

References

1. KATABATHINA VS, DASYAM AK, DASYAM N, HOSSEINZADEH K. Adult bile duct strictures: role of MR imaging and MR cholangiopancreatography in characterization. *Radiographics*. 2014;**34**(3):565-86.
2. KAPOOR BS, MAURI G, LORENZ JM. Management of Biliary Strictures: State-of-the-Art Review. *Radiology*. 2018;**289**(3):590-603.
3. PARSI MA. Common controversies in management of biliary strictures. *World J Gastroenterol*. 2017;**23**(7):1119-24.
4. ELSHIMI E, MORAD W, ELSHAARAWY O, ATTIA A. Optimization of biliary drainage in inoperable distal malignant strictures. *World J Gastrointest Endosc*. 2020;**12**(9):285-96.
5. ALATISE OI, OWOJUYIGBE AM, OMISORE AD, NDUBUBA DA, ABURIME E, DUA KS, et al. Endoscopic management and clinical outcomes of obstructive jaundice. *Niger Postgrad Med J*. 2020;**27**(4):302-10.
6. PARK DH. Endoscopic ultrasound-guided biliary drainage of hilar biliary obstruction. *J Hepatobiliary Pancreat Sci*. 2015;**22**(9):664-8.
7. FOGEL EL, SHERMAN S, DEVEREAUX BM, LEHMAN GA. Therapeutic biliary endoscopy. *Endoscopy*. 2001;**33**(1):31-8.
8. LAI EC, MOK FP, TAN ES, LO CM, FAN ST, YOU KT, et al. Endoscopic biliary drainage for severe acute cholangitis. *N Engl J Med*. 1992;**326**(24):1582-6.
9. ARTIFON EL, FERREIRA FC, SAKAI P. Endoscopic ultrasound-guided biliary drainage. *Korean J Radiol*. 2012;**13** Suppl 1(Suppl 1):S74-82.
10. SOOKLAL S, CHAHAL P. Endoscopic Ultrasound. *Surg Clin North Am*. 2020;**100**(6):1133-50.
11. SIMONS-LINARES CR, CHAHAL P. Advances in Interventional Endoscopic Ultrasound (EUS): A Technical Review. *J Clin Gastroenterol*. 2020;**54**(7):579-90.
12. JAGIELSKI M, SMOCZYŃSKI M, JABŁOŃSKA A, MAREK I, DUBOWIK M, ADRYCH K. The role of endoscopic ultrasonography in endoscopic debridement of walled-off pancreatic necrosis--A single center experience. *Pancreatol*. 2015;**15**(5):503-7.
13. NAM HS, KANG DH. [Endoscopic Ultrasound-guided Biliary Drainage]. *Korean J Gastroenterol*. 2017;**69**(3):164-71.
14. NUSSBAUM JS, KUMTA NA. Endoscopic Ultrasound-Guided Biliary Drainage. *Gastrointest Endosc Clin N Am*. 2019;**29**(2):277-91.
15. MORA SOLER AM, ÁLVAREZ DELGADO A, PIÑERO PÉREZ MC, VELASCO-GUARDADO A, MARCOS PRIETO H, RODRÍGUEZ PÉREZ A. Endoscopic ultrasound-guided choledochoduodenostomy after a failed or impossible ERCP. *Rev Esp Enferm Dig*. 2018;**110**(5):299-305.
16. GUPTA K, MALLERY S, HUNTER D, FREEMAN ML. Endoscopic ultrasound and percutaneous access for endoscopic biliary and pancreatic

- drainage after initially failed ERCP. *Rev Gastroenterol Disord*. 2007;**7**(1):22-37.
17. GIOVANNINI M, MOUTARDIER V, PESENTI C, BORIES E, LELONG B, DELPERO JR. Endoscopic Ultrasound-Guided Bilioduodenal Anastomosis: A New Technique for Biliary Drainage. *Endoscopy*. 2001;**33**(10):898-900.
 18. HAYAT U, BAKKER C, DIRWEESH A, KHAN MY, ADLER DG, OKUT H, *et al*. EUS-guided versus percutaneous transhepatic cholangiography biliary drainage for obstructed distal malignant biliary strictures in patients who have failed endoscopic retrograde cholangiopancreatography: A systematic review and meta-analysis. *Endosc Ultrasound*. 2022;**11**(1):4-16.
 19. KAHALEH M, ARTIFON ELA, PEREZ-MIRANDA M, GUPTA K, ITOI T, BINMOELLER KF, *et al*. Endoscopic ultrasonography guided biliary drainage: summary of consortium meeting, May 7th, 2011, Chicago. *World J Gastroenterol*. 2013;**19**(9):1372-9.
 20. NUNES N, FLOR DE LIMA M, CALDEIRA A, LEITE S, MARQUES S, MOREIRA T, *et al*. GRUPUGE PERSPECTIVE: Endoscopic Ultrasound-Guided Biliary Drainage. *GE, Portuguese Journal of Gastroenterology*. 2021;**28**(3):179-84.
 21. ZHAO XQ, DONG JH, JIANG K, HUANG XQ, ZHANG WZ. Comparison of percutaneous transhepatic biliary drainage and endoscopic biliary drainage in the management of malignant biliary tract obstruction: a meta-analysis. *Dig Endosc*. 2015;**27**(1):137-45.
 22. MAKMUN D, FAUZI A, ABDULLAH M, SYAM AF. The Role of EUS-BD in the Management of Malignant Biliary Obstruction: The Indonesian Perspective. *Diagn Ther Endosc*. 2017;**2017**:4856276.
 23. ALTONBARY AY, GALAL A, EL-NADY M, HAKIM H. Endoscopic ultrasound guided biliary drainage: a multicenter retrospective experience of a technique slowly gaining acceptance in Egypt. *Ther Adv Gastrointest Endosc*. 2019;**12**:2631774519889456-.
 24. LYU Y, LI T, CHENG Y, WANG B, CAO Y, WANG Y. Endoscopic ultrasound-guided vs ERCP-guided biliary drainage for malignant biliary obstruction: A up-to-date meta-analysis and systematic review. *Digestive and Liver Disease*. 2021;**53**(10):1247-53.
 25. UEMURA RS, KHAN MA, OTOCH JP, KAHALEH M, MONTERO EF, ARTIFON ELA. EUS-guided Choledochoduodenostomy Versus Hepaticogastrostomy: A Systematic Review and Meta-analysis. *Journal of Clinical Gastroenterology*. 2018;**52**(2).
 26. LI J, TANG J, LIU F, FANG J. Comparison of Choledochoduodenostomy and Hepaticogastrostomy for EUS-Guided Biliary Drainage: A Meta-Analysis. *Frontiers in Surgery*. 2022;**9**.
 27. FUGAZZA A, COLOMBO M, SPADACCINI M, VESPA E, GABBIADINI R, CAPOGRECO A, *et al*. Relief of jaundice in malignant biliary obstruction: When should we consider endoscopic ultrasonography-guided hepaticogastrostomy as an option? *Hepatobiliary & Pancreatic Diseases International*. 2022.
 28. SHIOMI H, NAKANO R, OTA S. Covered self-expandable metal stents for distal biliary obstruction from pancreatic carcinoma: what type of stent is preferred? *Clin Endosc*. 2022;**55**(3):369-71.
 29. OCHIAI K, FUJISAWA T, ISHII S, SUZUKI A, SAITO H, TAKASAKI Y, *et al*. Risk Factors for Stent Migration into the Abdominal Cavity after Endoscopic Ultrasound-Guided Hepaticogastrostomy. *Journal of Clinical Medicine*. 2021;**10**(14):3111.
 30. NAKAI Y, SAITO T, HAKUTA R, ISHIGAKI K, SAITO K, SAITO T, *et al*. Long-term outcomes of a long, partially covered metal stent for EUS-guided hepaticogastrostomy in patients with malignant biliary obstruction (with video). *Gastrointestinal Endoscopy*. 2020;**92**(3):623-31.e1.
 31. MANDAI K, UNO K, YASUDA K. Relationship Between the Intraoperative Stent Length in Endoscopic Ultrasound-Guided Hepaticogastrostomy and Surgically Altered Upper Gastrointestinal Anatomy in Patients With Malignant Biliary Obstruction. *Gastroenterology Res*. 2018;**11**(4):305-8.
 32. PAIK WH, PARK DH, CHOI J-H, CHOI JH, LEE SS, SEO DW, *et al*. Simplified fistula dilation technique and modified stent deployment maneuver for EUS-guided hepaticogastrostomy. *World J Gastroenterol*. 2014;**20**(17):5051-9.
 33. MIYANO A, OGURA T, YAMAMOTO K, OKUDA A, NISHIOKA N, HIGUCHI K. Clinical Impact of the Intra-scope Channel Stent Release Technique in Preventing Stent Migration During EUS-Guided Hepaticogastrostomy. *Journal of Gastrointestinal Surgery*. 2018;**22**(7):1312-8.
 34. HAMADA T, NAKAI Y, ISAYAMA H, KOIKE K. Tandem stent placement as a rescue for stent misplacement in endoscopic ultrasonography-guided hepaticogastrostomy. *Digestive Endoscopy*. 2013;**25**(3):340-1.
 35. ARTIFON EL, OKAWA L, TAKADA J, GUPTA K, MOURA EG, SAKAI P. EUS-guided choledochogastrostomy: an alternative for biliary drainage in unresectable pancreatic cancer with duodenal invasion. *Gastrointestinal endoscopy*. 2011;**73**(6):1317-20.
 36. ITOI T, ITOKAWA F, TSUCHIYA T, TSUJI S, TONOUZUKA R. Endoscopic ultrasound-guided choledochogastrostomy as an alternative extrahepatic bile duct drainage method in pancreatic cancer with duodenal invasion. *Digestive Endoscopy*. 2013;**25**(S2):142-5.
 37. UMEDA J, ITOI T, TSUCHIYA T, SOFUNI A, ITOKAWA F, ISHII K, *et al*. A newly designed plastic stent for EUS-guided hepaticogastrostomy: a prospective preliminary feasibility study (with videos). *Gastrointestinal endoscopy*. 2015;**82**(2):390-6. e2.
 38. GUO J, GIOVANNINI M, SAHAI AV, SAFTOIU A, DIETRICH CF, SANTO E, *et al*. A multi-institution consensus on how to perform EUS-guided biliary drainage for malignant biliary obstruction. *Endosc Ultrasound*. 2018;**7**(6):356-65.
 39. SCHMIDT A, RIECKEN B, RISCHE S, KLINGER C, JAKOBS R, BECHTLER M, *et al*. Wing-shaped plastic stents vs. self-expandable metal stents for palliative drainage of malignant distal biliary obstruction: a randomized multicenter study. *Endoscopy*. 2015;**47**(05):430-6.