

## Secondary anal fissures: a pain in the a\*\*

H. Ruymbeke<sup>1</sup>, J. Geldof<sup>2</sup>, D. De Looze<sup>2</sup>, M.A. Denis<sup>3</sup>, H. De Schepper<sup>4</sup>, P. Dewint<sup>4,5</sup>, I. Gijssen<sup>6</sup>, M. Surmont<sup>7</sup>, J. Wyndaele<sup>8</sup>, P. Roelandt<sup>8</sup>

(1) Department of Gastroenterology and Hepatology, VITAZ, Sint-Niklaas, Belgium; (2) Department of Gastroenterology and Hepatology, University Hospital Ghent, Ghent, Belgium; (3) Department of Gastroenterology and Hepatology, Cliniques Universitaires Saint-Luc, Brussels, Belgium; (4) Department of Gastroenterology and Hepatology, University Hospital Antwerp, Belgium; (5) Department of Gastroenterology and Hepatology, Maria Middelaers Hospital, Ghent, Belgium; (6) Department of Gastroenterology and Hepatology, Noorderhart Hospital, Pelt, Belgium; (7) Department of Gastroenterology and Hepatology, University Hospital Brussels, Brussels, Belgium; (8) Department of Gastroenterology and Hepatology, University Hospitals Leuven, Leuven, Belgium.

### Abstract

**An anal fissure is a painful tear of the sensitive anoderm, distally from the dentate line. It is a prevalent disorder and impairs quality of life dramatically. Typical or primary fissures are associated with constipation and mostly located at the posterior midline. About 1% of fissures are atypical in appearance and are generally secondary in nature. These secondary fissures should arouse attention and require further exploration for underlying conditions, such as Crohn's disease, malignancy, trauma or venereal infections. The aim of this manuscript is to provide a comprehensive review on the clinical aspects, evaluation and treatment of secondary anal fissures.** (*Acta gastroenterol. belg.*, 2023, 86, 58-67).

**Keywords:** anal fissure; secondary fissure; atypical fissure; anal pain.

**Abbreviations:** ACE, angiotensin converting enzyme; APLCD, anoperineal lesions in Crohn's disease; BT, botulinum toxin; CD, Crohn's disease; CMV, cytomegalovirus; GI, gastrointestinal; GPA, granulomatosis with polyangiitis; HIV, human immunodeficiency virus; HPV, human papillomavirus; HSV, herpes simplex virus; IHC, immunohistochemistry; IBD, inflammatory bowel disease; LGV, lymphogranuloma venereum; LIS, lateral internal sphincterotomy; MSM, men who have sex with men; PCR, polymerase chain reaction; SCCA, squamous cell carcinoma of the anus; SLE, systemic lupus erythematosus; STD, sexually transmittable disease; TNF, tumour necrosis factor; UC, ulcerative colitis.

### Introduction

An anal fissure is a tear of the sensitive anoderm in the anal canal, distally from the dentate line, somatically innervated and therefore painful. Anal fissure is the second most common reason for proctologic consultation after hemorrhoidal disease and has a cumulative lifetime incidence of 7.8 to 11.1%. Anal pain during and after defecation, often with bright red blood loss, is the cardinal symptom of an anal fissure. Diagnosis is based on typical symptoms and anal inspection. A fissure can be primary or secondary to other conditions.

Primary fissures have no clear underlying cause and are usually related to local trauma such as hard stools. Primary fissures are classified as acute (< 6 weeks) or chronic (> 6 weeks and/or clinical characteristics of chronicity/fibrosis). They are typically located on the posterior (and less often anterior) midline and associated with hypertonia of the internal anal sphincter (1,2).

About 1% of anal fissures are atypical. Atypical fissures are characterized by any of the following features: located in lateral/non-midline positions, multiple simultaneous sites, non-painful, nonlinear/excavated/indurated ulceration in the anal canal, associated with discharge of pus or bloody fluid, or associated with ulcerated and indurated skin tags. Atypical fissures are generally secondary in nature and therefore these atypical features require further exploration for underlying conditions, such as granulomatous diseases including Crohn's disease and tuberculosis, malignancy, chemotherapy, traumatic or iatrogenic causes, human immunodeficiency virus (HIV) and other venereal infections. Treatment is focused on the underlying condition (1,2).

The aim of this manuscript is to provide a comprehensive review on the clinical aspects, evaluation and treatment of secondary fissures. We will consecutively discuss anal fissures associated with systemic diseases, with venereal infections, fissures due to traumatic or iatrogenic causes and fissures seen in malignancy. Anal fissures in patients with HIV or patients receiving chemotherapy will not be discussed in this paper but will be included in the upcoming Belgian Consensus Guideline on the Management of Primary Anal Fissures (planned early 2023). As secondary fissures often show ulcerative features, the term ulcer/ulceration is often used instead of fissure.

### Systemic diseases

#### a) Crohn's disease (CD)

Anoperineal lesions in Crohn's disease (APLCD) are more prevalent than commonly perceived. They occur in up to 50% of patients with at least 10 years of Crohn's disease (CD) duration and their incidence increases with more distal colonic disease activity (3-5). Furthermore,

Correspondence to: Hannes Ruymbeke, MD, Department of Gastroenterology & Hepatology, VITAZ, Moerlandstraat 1, 9100 Sint-Niklaas, Belgium.  
Email: hannes.ruymbeke@vitaz.be

Submission date: 15/11/2022  
Acceptance date: 31/01/2023

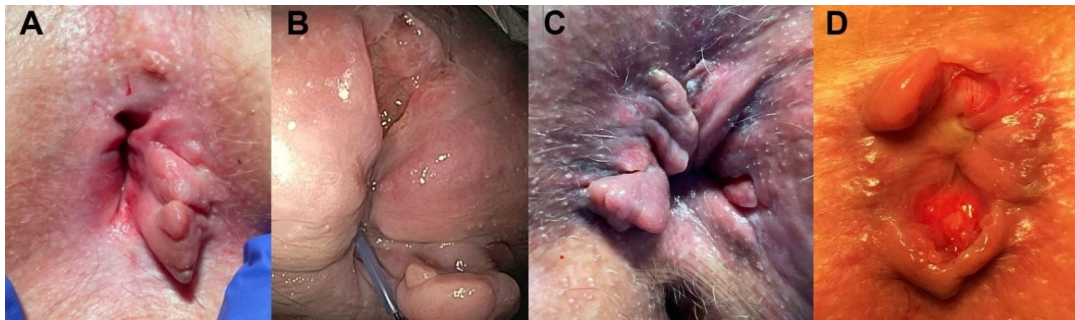


Figure 1. — Anal fissure in Crohn's disease.

APLCD and rectal involvement (proctitis) in general are associated with worse prognosis (3,6,7).

APLCD can be divided into primary and secondary lesions. Primary lesions reflect CD activity and include skin tags, fissures, ulcerations and granulomatous cutaneous lesions. Secondary lesions can evolve on their own, independent of endoluminal disease, and comprise abscesses, fistulae, anorectal strictures and anorectal cancers (3,5).

Anal fissures are more prevalent in CD patients compared to the general population and account for 21-35% of all APLCD. Fissures can progress to form deep or cavitating anal ulcerations (Fig. 1A, 1B, 1C) in 5-10% of CD patients (7-9). Unlike common fissures that are thought to be caused by spasm of the internal sphincter leading to reduction in blood flow and delayed healing, the fissures in Crohn's disease most probably have a different pathophysiology with direct ulceration caused by the inflammatory disease process (6,7).

#### Clinical presentation and diagnostic evaluation

APLCD in general can masquerade as other anorectal pathology and thus delay correct diagnosis and adequate treatment. Anal fissures in CD patients can be asymptomatic. However, anal discomfort including knife-like pain that worsens on bowel movements, bleeding, discharge and pruritus have been described in 44-70% of cases. Pain in CD-related anal fissures should always raise suspicion of superinfection. In cavitating ulcers the pain is often more severe and unremitting with consequential, significant impact on patients' quality of life (6,8,10-12).

Diagnosis of APLCD in general is based on a combination of clinical evaluation, exploration under anaesthesia, imaging and assessment of endoluminal disease (3, 11).

Clinical evaluation should include a complete proctologic examination including anoscopy if possible. If necessary this should be performed under general anaesthesia. CD-related anal fissures may have an atypical appearance with an eccentric (non-commissural) location (Fig. 1C) and can present as multiple simultaneous lesions (Fig. 1D). Ulcerations can occur along the entire length of the anal canal and extension beyond the dentate

line is possible. A pitted aspect (Fig. 1B) with prominent margins (Fig. 1C, 1D), an inflammatory character (Fig. 1B, 1D) and association with other types of APLCD can help distinguish CD-related from classical/typical anal fissures and ulcers. Upon healing, chronic induration and anal stenosis can occur (3,5,6,10,11).

The role of imaging (MRI and endoscopic ultrasonography) in the evaluation of anal fissures and ulcers is limited and predominantly focusses on assessment of sphincter integrity and exclusion of associated secondary, suppurative lesions (4,5). Biopsy of perianal tissue has a low sensitivity and specificity for histopathological diagnosis of CD. In case of suspicion of associated neoplastic transformation, it is however important to take biopsies (11,13-15).

#### Treatment

Currently there is no clear consensus on how to treat primary anoperineal Crohn lesions. In general, a multidisciplinary approach is advised including collaboration of gastroenterologists, surgeons and radiologists with the goal of symptom improvement and prevention of complications such as sphincter damage or secondary development of anal canal stenosis (5,10,11,16).

#### Medical treatment

Superficial anal fissures should initially be managed conservatively. This includes control of endoluminal disease and association of fibre supplements, in case of constipation. It is important to consider that unhealed fissure may progress to fistula or abscess in up to 20% of cases (6).

Topical treatment with nitroglycerin, nifedipine, diltiazem or botulinum toxin (BT) injection can be considered just as in typical fissures without underlying CD (4,6,11,12,17). There is anecdotal evidence on treatment with topical or local injection of steroids, topical 10% metronidazole, topical tacrolimus and hyperbaric oxygen treatment. Studies on these topical treatment modalities are however difficult to extrapolate due to small sample size and lack of control arm (3,8).

Apart from their role in controlling luminal disease activity, the efficacy of immunomodulators and biologic

therapies on primary APLCD remains largely unknown as there are very few dedicated controlled trials.

Thalidomide has shown a clinical effect in two CD patients with perianal ulcers and ciclosporin led to 70% healed ulcers in 20 patients after a median follow-up of 7 months (18,19). The efficacy of azathioprine monotherapy has not been proven in ulcerating perianal Crohn's disease (4,5).

A small retrospective study evaluated the efficacy of infliximab induction therapy in 29 CD patients with anal fissures and cavitating ulcers. At week 8, ulcer healing rate was 49% (20).

This result was consistent with the findings of a larger single-centre, retrospective, observational cohort study investigating the efficacy of infliximab in 99 patients with non-fistulising perianal CD. This study showed complete healing of the ulcers in 43% at 8 weeks and in 72.3% at long-term follow-up (median 175 weeks). Results for both superficial fissures and cavitating ulcers were similar and concomitant use of immunosuppressant and age under 40 years were found as predictors of long-term response (8).

Adalimumab has not specifically been studied in ulcerative perianal Crohn's disease (4).

As spontaneous healing is not uncommon, it remains uncertain to what extent the spontaneous evolution of these primary lesions over time attributes to the results of the above mentioned medical options as spontaneous healing is not uncommon (10). Before the biologic era, Buchmann *et al* demonstrated in a cohort of 109 patients with perianal CD that anal fissures only persisted in 19% of patients after 10 years follow-up (21). Furthermore, a single tertiary centre, prospective, observational study by Wallenhorst *et al.* on 154 CD patients with anal fissures and ulcers showed that there was no apparent benefit of treatment with anti-TNF $\alpha$  compared to a conservative treatment approach after a median follow-up duration of 65 weeks. Combination of biologic and immunosuppressant therapy neither led to significant differences in healing probability compared to biologic monotherapy or conservative treatment (9).

There are no data on combination of methotrexate with anti-TNF $\alpha$  inhibitors nor on specific efficacy of other biologics or small molecules for CD-related fissures and ulcers (5).

In conclusion, anal fissures linked to Crohn's disease are rather resistant to medical treatment, however, based on limited evidence, infliximab seems to be the preferred medication.

#### Surgical treatment

Historically there has been a concern for poor wound healing and increased complication rates after surgical treatment of anal fissures and anal ulcers in underlying Crohn's disease (4-6,10-12). Data on efficacy and safety of surgical treatment options such as sphincterotomy and fissurectomy are limited. A

literature review by Cracco *et al.* found 6 retrospective studies comprising 48 patients who were treated with lateral internal sphincterotomy (LIS) for anal fissures in underlying CD. Healing rate was 83%. However, 40% of patients suffered from postoperative complications, including patients without active rectal luminal disease (22). Targeted surgical treatment of primary APLCD should therefore be reserved for carefully selected symptomatic patients, refractory to medical treatment and preferably restricted to patients with well-controlled luminal disease activity (4,5,8,12). In perianal CD in general, surgical interventions should particularly aim to preserve the integrity of the anal sphincter complex given the increased risk of incontinence in these patients due to chronic diarrhoea, potential development of destructive perianal lesions and/or repeated operations (6). BT injection can be an alternative to LIS avoiding damage to the sphincter apparatus, risk of incontinence, and reducing wound healing complications (6).

In severely symptomatic and disabling perianal ulcerative disease, refractory to the above mentioned therapeutical options, faecal diversion with or without proctectomy should be considered (5,11).

#### b) Ulcerative colitis (UC)

In a study by Lindsey *et al.* 3 patients with UC were included and there was no significant difference in fissure healing between those with or without an underlying causative disorder (23). In a study by Madalinski *et al.* on the use of BT in secondary fissures, 4 patients with ulcerative colitis were studied. None of the fissures in these patients healed with BT. There was symptomatic improvement, but no relief of clinical symptoms (24).

#### c) Behçet's disease

Gastrointestinal (GI) manifestations are rare in Behçet's disease (5%) and generally very similar to those observed in inflammatory bowel disease (IBD). Ulcerations in the ileocecal region are most common, however the whole GI tract and the perianal skin can be involved. Perianal ulcers can be extremely painful, with heterogenous characteristics: superficial or deep, punctiform or giant, with a necrotic yellow bottom, possibly fistulizing and mutilating. Classical manifestations of Behçet's disease (oral/genital aphthosis, uveitis, joint pain, ...), a positive family history and histopathology can orient diagnosis, but differentiation with Crohn's disease is often difficult. In the absence of prospective studies, anorectal manifestations of Behçet's disease are often treated like perianal Crohn involvement or with colchicine or thalidomide (25,26).

#### d) Granulomatosis with polyangiitis (GPA)

Besides pulmonary, renal and ear-nose-throat manifestations, granulomatosis with polyangiitis (Wegener's

disease, GPA) can affect the GI tract, by means of ulcers. Anorectal ulcers/atypical fissures can develop after years of disease evolution, do not respond to topical treatment, can infect and can give rise to complex fistulas. Extraintestinal manifestations and histopathology can guide diagnosis, but histology is often non-specific. There are no specific studies on treatment for anorectal involvement, but the classical therapies for GPA with systemic corticosteroids, cyclophosphamide, rituximab or surgery are possible (25).

#### e) Systemic lupus erythematosus (SLE)

Half of the patients with SLE present with GI manifestations, mostly ulcerations throughout the GI tract. Penetrating and fistulizing anorectal ulcers have been described. Histology is non-specific and treatment is difficult with low efficacy of corticosteroids. Cases report benefit of tacrolimus or cyclophosphamide (25).

#### f) Sarcoidosis

GI tract involvement of sarcoidosis is rare (0.1-1.6%) and anal manifestation of sarcoidosis is even rarer, as the disease has a clear oro-anal gradient. The clinical aspect is variable but mostly ulcers are present. Perianal ulceration can be painful and may fistulize. Multi-organ involvement, elevated angiotensin converting enzyme (ACE) concentrations and histopathology are key to diagnosis, with presence of noncaseating epithelioid cell granulomas. The therapeutic approach of GI involvement is heterogeneous and includes wait-and-see in pauci-symptomatic patients, glucocorticoids, immunosuppressive therapy, and surgery (25-28).

### Infections

Infectious anal ulcerations and proctitis can occur after contamination of the perianal region due to sexual genital or anal mucosal contact, but sometimes also via digital contact and foreign objects. *Neisseria gonorrhoeae*, *Chlamydia trachomatis*, *Treponema pallidum* and herpes simplex virus (HSV) are the most common sexually transmitted anorectal pathogens. In Western countries, infectious anal ulceration is typically encountered with HSV, *Treponema* or *Chlamydia serovar L1-L3* infection. Anal cytomegalovirus (CMV) ulcerations can be seen in immunocompromised patients. Donovanosis, chancroid and amebiasis are prevalent in tropical regions, as well as lymphogranuloma venereum (LGV), caused by *Chlamydia serovar L1-L3*. However, LGV became also endemic in Western countries in the last 2 decades, especially among men who have sex with men (MSM). A history of sexual transmittable disease (STD), sexual high-risk behaviour (MSM, multiple sex partners, ...), presence of purulent anal discharge, tenesmus, inguinal adenopathy or concomitant proctitis should raise suspicion of an infectious cause of anal fissures.

Diagnosis can often be suspected clinically, but additional testing is necessary. Diagnosis can be made using polymerase chain reaction (PCR) testing (anal swab in the ulceration or through the anal canal or the anoscope in case of discharge) for *Chlamydia*, gonococcal, CMV, syphilis and monkeypox infection, by bacterial culture for *Neisseria* and by serology for syphilis. In some cases, viral culture for HSV/CMV can be useful. There's a duty to report syphilis and gonococcal infection in Belgium.

Co-infections are frequent and should therefore be ruled out, including STD screening for HIV, hepatitis B and C infection. As the majority of anorectal chlamydia and gonococcal infections are asymptomatic, exclusion of anorectal infections is generally indicated as part of standard screening for STD, especially when there is a history of receptive anal contact. Adequate counselling on prevention and transmission risk and the implications for the health of themselves and their partner(s) is recommended. This also includes partner notification and treatment if necessary. Follow-up after treatment is mandatory (26,29,30).

#### a) Chlamydia

Primoinfection with *Chlamydia trachomatis serotype D-K* is typically asymptomatic or may cause mild superficial localized mucosal inflammation such as urethritis or proctitis. In HIV+ MSM *Chlamydia trachomatis serotype L1-L3* are often encountered, giving rise to a more severe disease course called lymphogranuloma venereum. An anorectal ulceration (Fig. 2), papule or pustule is seen 2-60 days after exposure, which will often heal spontaneously. It can be painful but is mostly painless and deep (Fig. 2). Subsequently, about 1-6 weeks after the primary lesion, an ulcerative proctitis and inguinal lymphadenopathy will develop, which can be accompanied by lower back or lower abdominal pain and constitutional symptoms (fever, chills, malaise, myalgia, arthralgia). LGV should be considered in MSM with suspected chronic inflammatory bowel disease.

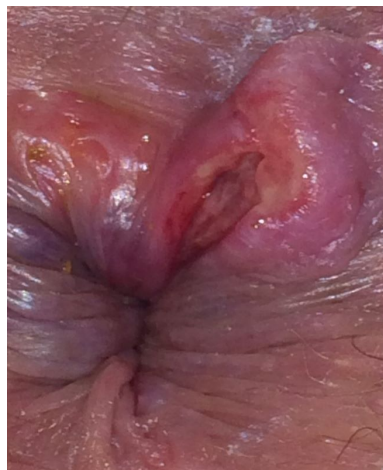

Figure 2. — Anal fissure in lymphogranuloma venereum.

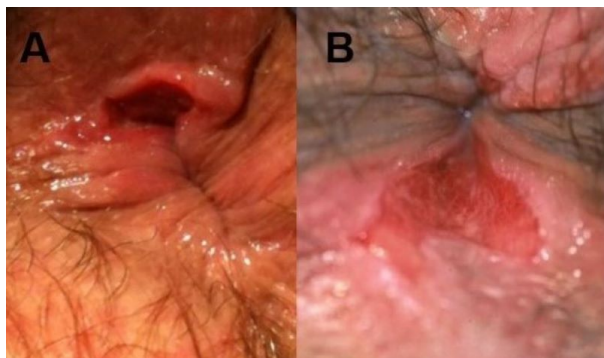


Figure 3. — Anal fissure in syphilis.

A tertiary phase with chronic lymphangitis and in case of rectal involvement also abscess formation, stenosis and fistulae formation is possible (26,29,31). Those with a clinical syndrome consistent with LGV should be treated empirically at the time of initial visit, even prior to the results of chlamydial diagnostic testing. In MSM Chlamydia trachomatis positive samples should be forwarded for LGV genotyping (31). First line treatment for LGV is doxycycline 2x100mg/d for 3 weeks or azithromycin 1g/week for 3 weeks, in non-LGV treatment duration is 1 week. Follow-up is recommended until clinical healing and repeated PCR testing until negative results in case of LGV (30,31).

#### b) Syphilis

Incidence of anorectal syphilis is increasing. The primary phase of infection with *Treponema pallidum* is characterized by an anal chancre (Fig. 3A, 3B) at the site of inoculation with regional lymphadenopathy. This ulcer is primary superficial, single, painless, indurated with a clean base (Fig. 3B), has serous discharge, is never blistering and presents sometimes with oedematous edges (Fig. 3A). However, lesions are often atypical in appearance and may be multiple, painful, deep (Fig. 3A) and indistinguishable from herpes (26,32). Lower GI syphilis is a rare manifestation of early syphilis (33). Endoscopic evaluation of syphilitic proctitis can show large, multiple irregular ulcers, sometimes opposite to one another or eccentrically located. Spontaneously resolving of the chancre occurs after 3-4 weeks. If left untreated, secondary (multisystem involvement due to bacteraemia including mucocutaneous manifestations) and tertiary (neurological, cardiovascular) syphilis will develop in one-third and 10% of patients, respectively. Any anogenital ulcer should be considered syphilitic unless proven otherwise, and serological retesting is sometimes needed to exclude a diagnosis (32). Apart from serology, anorectal syphilis can be diagnosed by the detection of spirochetes in the exudate of the ulcer or by an anorectal mucosal or ulcer swab for PCR (29). Treatment with benzathine-penicillin G (2.4 million units intramuscular in a single dose) is very efficacious in case of recent (<1 year) infection. Treatment response should

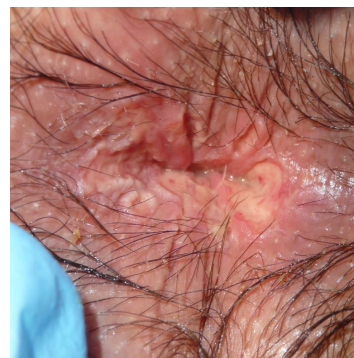

Figure 4. — Anal fissure in herpes simplex virus infection.

be monitored with serology. Nontreponemal test antibody (VDRL or RPR) titres should diminish with a fourfold change in titre, whereas TPHA will remain positive. Re-infection is possible (30, 32).

#### c) Herpes simplex virus (HSV)

HSV is one of the commonest STD worldwide and the most frequent cause of infectious genital ulceration. Anogenital HSV type 1 and 2 have similar clinical features (26,34). Primoinfection is often asymptomatic, or can lead to painful perianal or anorectal ulcerations (Fig. 4). Classical genital herpes can be recognized by the presence of typical papular lesions progressing to confluent vesicular eruption and painful ulcer formation (Fig. 4), associated with local adenitis, but features can be highly variable. General symptoms such as fever and asthenia can occur as well as dysuria, urinary retention, sacral paraesthesia or proctitis. In immunocompromised patients extensive and severe disease is possible (26, 34). Dependence upon clinical diagnosis alone should be avoided, so PCR testing is now the gold standard, rather than cell culture (34). Immediate treatment (on clinical suspicion alone) is advised and can be highly effective. Aciclovir 400 mg orally 3x/day for 5-10 days or valaciclovir 500mg 2x/day is recommended (29,30,34).

#### d) Tuberculosis

GI involvement in tuberculosis is rare (1% of all cases), with the ileocecal region as most common site. Perianal tuberculosis is anecdotal, mostly in association with HIV infection. Anal tuberculosis can present as non-healing ulcer-like fissures, but the most common type of anal involvement is the ulcerative form. These ulcers typically appear as recurrent anal lesions with well-defined boundaries and purulent exudates. Hemorrhoidal nodules, abscesses with complex, recurrent and refractory anoperineal fistulae and miliary forms are also possible. GI and anal tuberculosis is hard to differentiate from Crohn's disease clinically, endoscopically and histologically. Demographic and health background, immunodeficiency, respiratory or other systemic complaints (fever, night sweats, weight loss), inguinal

lymphadenopathy, non-healing lesions can raise suspicion of tuberculosis. A positive PCR (lesion swab), Ziehl-Neelsen acid-fast bacteria stain in the discharge or on biopsy, Interferon-Gamma Release Assays (IGRA) or culture for mycobacterium tuberculosis can help to confirm the diagnosis. Histology can show caseating granulomas. Therapy involves conventional anti-mycobacterial agents for at least 6 months and up to 2 years in complicated disease, with surgical treatment if necessary (35-40).

#### e) *Gonorrhoea*

Gonorrhoea is caused by *Neisseria gonorrhoea* and incidence rates are increasing. Infection is mostly asymptomatic but can lead to a purulent proctitis (41). In rare cases, it can present as superficial anal ulcerations. As the prevalence of multidrug-resistant *Neisseria* increases, culture for surveillance purposes becomes increasingly important (29). Treatment with ceftriaxone 500mg or 1g IM in a single dose in combination with azithromycin (1g in a single dose) or doxycycline (100 mg twice daily for 7 days) is recommended in most cases, monotherapy only in well-controlled settings and when *Chlamydia* co-infection has been ruled out (30,41). Confirmation of cure is recommended in all gonococcal infections to ensure eradication and identify resistance (41).

#### f) *Cytomegalovirus (CMV)*

Cytomegalovirus usually spreads during casual contact, but can be transmitted via unprotected sex. Although anal lesions are very rare, immunocompromised patients can present with anal ulcerations, with or without associated systemic CMV infection or CMV colitis. These lesions are often painful and can be itchy or bleeding. They occur perianally and in the anal canal, are typically confluent and eczematiform and can be superficial or deep. The triad of mononucleosis-like illness with rectal symptoms after condomless anal intercourse is pathognomonic for sexually transmitted CMV proctitis. Histology can show intranuclear or intracytoplasmic inclusions of CMV or show viral antigens by immunohistochemistry (IHC) or PCR. Serum CMV PCR is often positive. The role of antiviral therapy in primary CMV proctitis has not been defined and it is probably not necessary. In case of progressive CMV colitis, treatment with (val)ganciclovir is effective (26,29,42,43).

#### g) *Haemophilus ducreyi*

*Haemophilus ducreyi* infection is the number 1 anal ulceration due to an STD in tropical countries and can lead to chancroid ulcer, typically round or oval, deep, not indurated, with necrotic bottom and a double yellow and red border. Voluminous and painful unilateral satellite inguinal adenopathy is typical, which may fistulize to the skin, producing pus (brown chocolate). Diagnosis is

clinical or by showing the presence of the bacillus on direct examination or culture. Treatment with Azithromycin 1 g or Ceftriaxone 250 mg IM is efficacious (30).

#### h) *Donovanosis*

Granuloma inguinale (donovanosis) is a genital ulcerative disease caused by the intracellular Gram-negative bacterium *Klebsiella granulomatis*, characterized by painless, slowly progressive, highly vascular, long indurated fissures/ulcerative lesions on the genitals or perineum without regional lymphadenopathy. Extragenital infection can occur. Bacterial culture is difficult. Diagnosis requires visualization of dark-staining Donovan bodies on tissue crush preparation or biopsy. Long term antibiotic treatment is necessary (30).

#### i) *Amoebiasis*

Infection with *Entamoeba histolytica* is common in tropical and sub-tropical regions and is often asymptomatic or self-limiting. If symptomatic, typical presentation is amoebic dysentery, possibly with hematogenous spread resulting in liver abscess and disseminated organ disease. In rare cases infection can lead to painful cutaneous and perianal ulcerations, often accompanied by proctitis or colitis. Cutaneous ulcers are often solitary, necrotizing and with indurated base. Histology can reveal trophozoites and PCR of rectal exudate or ulcers can be positive for *E. histolytica*. Stool test can show cyst forms or trophozoites and serum antibodies are positive in 75-85% of the cases. Any infection should be treated, therapy of choice is metronidazole 750mg 3x/d for 5-10 days (29,44,45).

#### j) *Monkeypox*

In May 2022 a new monkeypox outbreak was observed outside Africa, mostly among men, particularly MSM. The current outbreak has specific characteristics. The febrile prodrome may be absent and skin/mucosal lesions frequently affect the genital, perineal and anal regions. Anal and rectal vesicles and ulcers are frequently encountered, often causing severe unprecedented anal pain, but they are usually self-limiting. PCR can confirm diagnosis. Treatment is mainly supportive, focusing on pain relief. Antiviral therapy with tecovirimat may shorten duration of illness (46,47).

### Traumatic and iatrogenic causes

#### a) *Surgery*

Various perianal lesions may be due to anal surgery, such as skin tags, anal canal deformation, stenosis or fissure-like wounds (26).

### b) Radiation

Pelvic radiation disease can result from ionizing radiation-induced damage to surrounding non-cancerous tissues. Acute proctitis occurs frequently during or within 3 months of radiotherapy, typically with superficial and transitory lesions. Chronic, delayed radiation disease is less frequent, with presence of telangiectasia. Ulcerations in the rectum and less frequently in the anal canal can occur as well. They are mostly deep, indurated and often hard to differentiate from malignant lesions (26,48,49). Especially after radiotherapy for anal canal cancer perianal and anal ulcerations can be encountered. Oblak *et al.* describes non-healing anal ulcers in 4% after radiochemotherapy for anal carcinoma (50). A systematic review by Pan *et al.* on late GI complications after radiation therapy for anal canal cancer report anorectal ulceration in 1 to 22.6% of patients (51). Histology is key. Treatment is difficult, options include hyperbaric oxygen therapy (26,52).

### c) Medication

Nicorandil, an oral anti-angina pectoris therapy, is known to cause oral, intestinal and anal fissure or ulceration (26,53). An incidence of 4 per 1000 patients on Nicorandil each year is estimated (54). The ulcers are usually large and can give symptoms of pain, mucus discharge and rectal bleeding. They do not respond to any specific treatment, but only to dose reduction or cessation of the drug, with healing in the following months (55). Nicorandil is not available in Belgium.

Local therapies with ointments such as imiquimod or catechins can lead to various cutaneous reactions including erosions and erythema (26).

Case reports describe anorectal ulcerations after repeated administration of NSAID or ergotamine suppositories (26, 56).

A retrospective analysis of patients receiving angiogenesis inhibitors (e.g. bevacizumab) found that symptomatic anal ulcers occurred in 4.2%, which can compromise the continuation of cancer therapy (57).

### d) Enema

When inadequate administration of an enema occurs, the canula may damage the mucosa and lead to (peri) anal or rectal ulceration. Caustic lesions may arise from direct toxic mucosal effects of the product administered. Thermic lesions have been reported as well. Traumatic lesions can cause severe anorectal bleeding or rapid necrosis presenting as an extensive ulceration, secondary to injection and diffusion of the product in the submucosal layer, possibly leading to necrotizing fasciitis (26).

### e) Corpus alienum

Entrapped anorectal foreign bodies are rare, but occur more frequently in recent years in clinical practice,

affecting mainly males (58). The majority is related to sexual behaviour (anorectal erotism in 80%, sexual assault in 10%), but they can also result from self-treatment for anorectal disease (retained enema tips, thermometer), ingestion, accidents or drug smuggling (59,60). Forced introduction through the anus may cause anal lesions (such as erosions and ulcers), as do the attempts of patients to remove the objects themselves before presenting to the hospital (60). Severe injury to the anal sphincter and rectum is possible. Diagnosis is confirmed by plain abdominal radiographs and anorectal examination. Perforation should be ruled out. Other complications include pelvic abscess, sepsis, anal sphincter damage and anal bleeding. Manual extraction without anaesthesia is only possible for very distal objects. Patients with more proximal positioned foreign bodies generally require general anaesthesia to achieve complete relaxation of the anal sphincters to facilitate extraction. Transanal extraction is successful in most cases. Endoscopic vision and guidance can protect the patients from iatrogenic injuries and is useful after extraction to assess severity of injury. Open surgery should be reserved only for patients with perforation, peritonitis, or impaction of the foreign body (59,60).

### f) Anal sex/sexual abuse

Anal sexual contacts are frequent in both homo- and heterosexuals. Consensual sexual acts with the use of lubricants normally don't cause significant durable lesions. In contrast, when performed brutally, without lubricant or consent, traumatic and painful lesions may occur. Anal irritation with erythema, itching and mucous discharge are more frequently observed than mucosal lesions at the anal region (fissuration) or rectal mucosa. Bruises, reactive hemorrhoidal thrombosis and anal sphincter lesions can occur as well (26,61).

A Belgian study found sexual abuse as the aetiological factor for chronic anal fissure in 19% of 80 adult patients. Anismus is frequently associated in this population, leading to lower healing rates. A multidisciplinary approach is crucial, including conservative, surgical, physiotherapeutic, psychological and psychiatric treatments (62). Due to mucosal lesions in the anorectal region, transmission of STD is facilitated and this should be screened for (26).

It is worth noting that detection of anogenital lesions, including anal fissures, during a paediatric consultation should make practitioners aware of the possibility of sexual abuse (63).

### Malignancy

Although anal cancer is rare (1-2 cases per 100 000 person years), incidence is increasing. Squamous cell carcinoma of the anus (SCCA), related to Human Papilloma Virus (HPV) infection, is the most common type of anal cancer. Although anal cancer is mostly

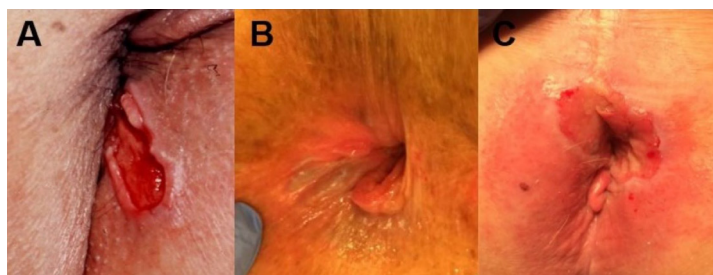


Figure 5. — Anal carcinoma presenting as an anal fissure.

encountered in women over 50 years old, high-risk groups are patients with immunosuppression for solid-organ transplantation, HIV, MSM and women with a history of HPV-related gynaecological precancerous lesions or cancer. Additional risk factors include smoking, genital warts and a history of receptive anal sexual intercourse (26,64,65). Multiple studies report that benign anorectal conditions such as anal fissures or fistulas are associated with an increased risk of anal cancer as well (65-67). HPV vaccination is expected to be the long-term solution to prevention of SCCA, but the impact will not be seen for decades (64). Primary adenocarcinoma, small cell carcinoma, metastatic lesions, primary skin tumours such as basal cell carcinoma or melanoma, lymphoma, leiomyoma or Kaposi sarcoma are more rare types of anal cancer (26,68). The clinical aspect of anal cancer can be variable. Symptoms of persisting anal bleeding or discharge, pain, itching, faecal incontinence or feeling of a mass can reveal an anal cancer.

SCCA can present as a bulging mass or an extensive ulcerative (Fig. 5A) or polypoid lesion, but in early stages it is often more difficult to differentiate from benign anorectal disease and abnormalities may be subtle. Early stages can present as a small perianal lesion similar to an anal skin tag (Fig. 5B), as an indurated erythema (Fig. 5C), a zone of (de)pigmentation (Fig. 5C), or as a non-healing, indurated fissure or ulceration (Fig. 5A) (26,68,69). Even acute haematological malignancies can present as an anal fissure or one or multiple anal ulcers, often necrotic (26,70).

The clinical suspicion of anal carcinoma should be high in patients with non-healing or indurated anal fissures, fissures in atypical positions or with ulcerated anal tags, especially in high-risk patients (68,69). In these cases biopsies should be taken, as histopathology is key to diagnosis.

If there's a clinical suspicion for primary anal fissure, but without clear visualisation of the linear tear and if symptoms persist, exploration under anaesthesia should be considered to have a clear diagnosis and rule out malignancy (26,69). Therapy depends on the type of carcinoma. In case of SCCA chemoradiation remains the standard of care (65,68).

## Conclusion

Although the majority of anal fissures are primary in nature, clinicians should be aware of the features of

atypical or secondary anal fissures. The first step is to recognize them, subsequently further exploration for underlying diseases is required.

Frequent causes of secondary anal fissures include Crohn's disease and sexually transmittable diseases, but anal cancer, rare systemic diseases and traumatic or iatrogenic causes should be considered as well. A thorough medical history and clinical examination are crucial. In case of atypical fissures, STD screening should be performed and the threshold for histopathological analysis, ileocolonoscopy or exploration under general anaesthesia should be low, to rule out malignancy or endoluminal inflammation.

## Conflict of interest statement or relevant financial disclosures

All authors report no conflict of interest or relevant financial disclosures considering this project.

## References

- MATHUR N., QURESHI W. Anal fissure management by the gastroenterologist. *Curr Opin Gastroenterol.*, 2020, **36** : 19-24.
- SALATI SA. Anal Fissure - an extensive update. *Pol Przegl Chir.*, 2021, **93** : 46-56.
- ATIENZA P., KSIAA M. Particular aspects of proctology for anoperineal lesions in Crohn's disease. *J Visc Surg.*, 2015, **152** : S45-53.
- BOUCHARD D., ABRAMOWITZ L., BOUGUEN G., BROCHARD C., DABADIE A., DE PARADES V. *et al.* Anoperineal lesions in Crohn's disease: French recommendations for clinical practice. *Tech Coloproctol.*, 2017, **21** : 683-91.
- BOUCHARD D., BROCHARD C., VINSON-BONNET B., STAUMONT G., ABRAMOWITZ L., BENFREDJ F. *et al.* How to manage anal ulcerations and anorectal stenosis in Crohn's disease: algorithm-based decision making: French National Working Group Consensus 2018. *Tech Coloproctol.*, 2019, **23** : 353-60.
- D'UGO S., FRANCESCHILLI L., CADEDDU F., LECCESI L., DEL VECCHIO BLANCO G., CALABRESE E. *et al.* Medical and surgical treatment of haemorrhoids and anal fissure in Crohn's disease: a critical appraisal. *BMC Gastroenterol.*, 2013, **13** : 47.
- MALATY H.M., SANSGIRY S., ARTINYAN A., HOU J.K. Time Trends, Clinical Characteristics, and Risk Factors of Chronic Anal Fissure Among a National Cohort of Patients with Inflammatory Bowel Disease. *Dig Dis Sci.*, 2016, **61** : 861-4.
- BOUGUEN G., TROUILLOUD I., SIPROUDHIS L., OUSSALAH A., BIGARD M-A., BRETAGNE J-F., PEYRIN-BIROULET L. Long-term outcome of non-fistulizing (ulcers, stricture) perianal Crohn's disease in patients treated with infliximab. *Aliment. Pharmacol. Ther.*, 2009, **30** : 749-56.
- WALLENHORST T., BROCHARD C., LE BALCH E., BODERE A., GARROS A., MERLINI-L'HERITIER A. *et al.* Anal ulcerations in Crohn's disease: Natural history in the era of biological therapy. *Dig Liver Dis.*, 2017, **49** : 1191-5.



10. SANDBORN W.J., FAZIO V.W., FEAGAN B.G., HANAUER S.B. AGA technical review on perianal Crohn's disease. *Gastroenterology*, 2003, **125** : 1508-30.
11. POGACNIK J.S., SALGADO G. Perianal Crohn's Disease. *Clin Colon Rectal Surg.*, 2019, **32** : 377-85.
12. LIGHTNER A.L. Perianal Crohn's Disease. *Dis Colon Rectum*, 2020, **63** : 1023-6.
13. TARAZI R., NELSON R.L. Anal adenocarcinoma: a comprehensive review. *Semin Surg Oncol.*, 1994, **10** : 235-40.
14. FRICK E.J., LAPOS L., VARGAS H.D. Solitary neurofibroma of the anal canal: report of two cases. *Dis Colon Rectum*, 2000, **43** : 109-12.
15. ERHAN Y., SAKARYA A., AYDEDE H., DEMIR A., SEYHAN A., ATICI E. A case of large mucinous adenocarcinoma arising in a long-standing fistula-in-ano. *Dig Surg.*, 2003, **20** : 69-71.
16. KENNEDY N.A., JONES G.R., LAMB C.A., APPLEBY R., ARNOTT I., BEATTIE R.M. *et al.* British Society of Gastroenterology guidance for management of inflammatory bowel disease during the COVID-19 pandemic. *Gut*, 2020, **69** : 984-90.
17. STEWART D.B., GAERTNER W., GLASGOW S., MIGALY J., FEINGOLD D., STEELE S.R. Clinical Practice Guideline for the Management of Anal Fissures. *Dis Colon Rectum*, 2017, **60** : 7-14.
18. CAT H., SOPHANI I., LEMANN M., MODIGLANI R., SOLUE J.C. Cyclosporin treatment of anal and perianal lesions associated with Crohn's disease. *Turk J Gastroenterol.*, 2003, **14** : 121-7.
19. PLAMondon S., Ng S.C., Kamm M.A. Thalidomide in luminal and fistulizing Crohn's disease resistant to standard therapies. *Aliment Pharmacol Ther.*, 2007, **25** : 557-67.
20. OURAGHI A., NIEUVIARTS S., MOUGENEL J.L., ALLEZ M., BARTHET M., CARBONNEL F. *et al.* [Infliximab therapy for Crohn's disease anoperineal lesions]. *Gastroenterol Clin Biol.*, 2001, **25** : 949-56.
21. BUCHMANN P., KEIGHLEY M.R., ALLAN R.N., THOMPSON H., ALEXANDER-WILLIAMS J. Natural history of perianal Crohn's disease. Ten year follow-up: a plea for conservatism. *Am J Surg.*, 1980, **140** : 642-4.
22. CRACCO N., ZINICOLA R. Sphincterotomy for anal fissure in Crohn's disease: is it dangerous? *Int J Colorectal Dis.*, 2016, **31** : 761.
23. LINDSEY I., JONES O.M., CUNNINGHAM C., GEORGE B., MORTENSEN N.J. Botulinum toxin as second-line therapy for chronic anal fissure failing 0.2 percent glyceryl trinitrate. *Dis Colon Rectum*, 2003, **46** : 361-6.
24. MADALIŃSKI M.H. Botulinum toxin for the treatment of secondary chronic anal fissure. *Tech Coloproctol.*, 2003, **7** : 85-8; comment 8.
25. EGAL A., LONDON J., LIDOVE O., ATIENZA P., ETIENNEY I. Manifestations ano-rectales des maladies systémiques. *Rev Med Interne.* 2019, **40** : 729-32.
26. FATHALLAH N., DE PARADES V. Atlas de proctologie. Arcueil, Cobham (Grande-Bretagne): *John Libbey Eurotext*, 2021.
27. FATHALLAH N., VALEYRE D., LÉVY M., FRAITAG S., DE PARADES V. Anal manifestation of sarcoidosis. *Presse Med.*, 2016, **45** : 146-7.
28. BRITO-ZERÓN P., BARI K., BAUGHMAN R.P., RAMOS-CASALS M. Sarcoidosis Involving the Gastrointestinal Tract: Diagnostic and Therapeutic Management. *Am J Gastroenterol.*, 2019, **114** : 1238-47.
29. DE VRIES H.J.C., NORI A.V., KIELBERG LARSEN H., KREUTER A., PADOVESE V., PALLAWELA S. *et al.* 2021 European Guideline on the management of proctitis, proctocolitis and enteritis caused by sexually transmissible pathogens. *J Eur Acad Dermatol Venereol.*, 2021, **35** : 1434-43.
30. WORKOWSKI K.A., BACHMANN L.H., CHAN P.A., JOHNSTON C.M., MUZNY C.A., PARK I. *et al.* Sexually Transmitted Infections Treatment Guidelines, 2021. *MMWR Recomm Rep.*, 2021, **70** : 1-187.
31. O'BYRNE P., MACPHERSON P., DELAPLANTE S., METZ G., BOURGAULT A. Approach to lymphogranuloma venereum. *Can Fam Physician.*, 2016, **62** : 554-8.
32. JANIER M., UNEMO M., DUPIN N., TIPLICA G.S., POTOČNIK M., PATEL R. 2020 European guideline on the management of syphilis. *J Eur Acad Dermatol Venereol.*, 2021, **35** : 574-88.
33. FERZACCA E., BARBIERI A., BARAKAT L., OLAVE M.C., DUNNE D. Lower Gastrointestinal Syphilis: Case Series and Literature Review. *Open Forum Infect Dis.*, 2021, **8** : ofab157.
34. PATEL R., KENNEDY O.J., CLARKE E., GERETTI A., NILSEN A., LAUTENSCHLAGER S. *et al.* 2017 European guidelines for the management of genital herpes. *Int J STD AIDS.*, 2017, **28** : 1366-79.
35. ROMELAER C., ABRAMOWITZ L. [Anal abscess with a tuberculous origin: report of two cases and review of the literature]. *Gastroenterol Clin Biol.*, 2007, **31** : 94-6.
36. MILGROM Y., GOLDMAN G., HILLEL A.G., POJUROVSKY S., ACKERMAN Z. Tuberculosis: a rare cause of peri-anal disease. *Isr Med Assoc J.*, 2013, **15** : 782-3.
37. TAGO S., HIRAI Y., AINODA Y., FUJITA T., TAKAMORI M., KIKUCHI K. Perianal tuberculosis: A case report and review of the literature. *World J Clin Cases.*, 2015, **3** : 848-52.
38. AZADI A., JAFARPOUR FARD P., SAGHARJOGHI FARAHANI M., KHODADADI B., ALMASIAN M. Anal tuberculosis: A non-Healing anal lesion. *IDCases*, 2018, **12** : 25-8.
39. GARG P., GARG M., DAS B.R., KHADAPKAR R., MENON G.R. Perianal Tuberculosis: Lessons Learned in 57 Patients From 743 Samples of Histopathology and Polymerase Chain Reaction and a Systematic Review of Literature. *Dis Colon Rectum.*, 2019, **62** : 1390-400.
40. STROBL J., SALAT A., BAUER W., STARY G. Perianal ulceration as primary presentation in a patient with disseminated multi-drug resistant tuberculosis. *J Dtsch Dermatol Ges.*, 2020, **18** : 372-4.
41. UNEMO M., ROSS J., SERWIN A.B., GOMBERG M., CUSINI M., JENSEN J.S. 2020 European guideline for the diagnosis and treatment of gonorrhoea in adults. *Int J STD AIDS.*, 2020, 956462420949126.
42. ALOI F., SOLAROLI C., PAPOTTI M. Perianal cytomegalovirus ulcer in an HIV-infected patient. *Dermatology*, 1996, **192** : 81-3.
43. SNAUWAERT C., VANDECASSTEELE S.J., LAUKENS P. A Painful Perianal Lesion. Cytomegalovirus-Associated Perianal Ulcers. *Gastroenterology*, 2015, **149** : e11-2.
44. KROFT E.B., WARRIS A., JANSEN L.E., VAN CREVEL R. [A Dutchman from Mali with a perianal ulcer caused by cutaneous amoebiasis]. *Ned Tijdschr Geneesk.*, 2005, **149** : 308-11.
45. POSCH C., WALOCHNIK J., SCHULLER-LUKIC B., WEIHSENGRUBER F., GEPPERT F., RAPPERSBERGER K. Perianal ulcer - amoebiasis cutis. *J Dtsch Dermatol Ges.*, 2011, **9** : 649-50.
46. MAILHE M., BEAUMONT AL., THY M., LE PLUART D., PERRINEAU S., HOUHOU-FIDOUH N. *et al.* Clinical characteristics of ambulatory and hospitalized patients with monkeypox virus infection: an observational cohort study. *Clin Microbiol Infect.*, 2022.
47. PFÄFFLIN F., WENDISCH D., SCHERER R. *et al.* Monkeypox in-patients with severe anal pain. *Infection*, 2022.
48. BORZOMATI D., VALERI S., RIPETTI V., VINCENZI B., RABITTI C., PERSICHETTI P. *et al.* Persisting perianal ulcer after radiotherapy for anal cancer: recurrence of disease or late radiation-related complication? *Hepatogastroenterology*, 2005, **52** : 780-4.
49. MORRIS K.A., HABOUBI N.Y. Pelvic radiation therapy: Between delight and disaster. *World J Gastrointest Surg.*, 2015, **7** : 279-88.
50. OBLAK I., PETRIC P., ANDERLUH F., VELENIK V., HUDEJ R., FRAS A.P. Anal cancer chemoradiation with curative intent - a single institution experience. *Neoplasma*, 2009, **56** : 150-5.
51. PAN Y.B., MAEDA Y., WILSON A., GLYNNE-JONES R., VAIZEY C.J. Late gastrointestinal toxicity after radiotherapy for anal cancer: a systematic literature review. *Acta Oncol.*, 2018, **57** : 1427-37.
52. ALI F., HU KY. Evaluation and Management of Chronic Radiation Proctitis. *Dis Colon Rectum*, 2020, **63** : 285-7.
53. EGREDD M. Nicorandil-associated ulcerations. *Eur J Gastroenterol Hepatol.* 2007, **19** : 395-8.
54. COLVIN H.S., BARAKAT T., MOUSSA O., BABU H., SLAUGHTER T., PALMER J.G. *et al.* Nicorandil associated anal ulcers: an estimate of incidence. *Ann R Coll Surg Engl.*, 2012, **94** : 170-2.
55. AKBAR F., MAW A., BHOWMICK A. Anal ulceration induced by nicorandil. *BMJ.*, 2007, **335** : 936-7.
56. GIZZI G., VILLANI V., BRANDI G., PAGANELLI G.M., DI FEBE G., BIASCO G. Ano-rectal lesions in patients taking suppositories containing non-steroidal anti-inflammatory drugs (NSAID). *Endoscopy*, 1990, **22** : 146-8.
57. BERGAMO F., LONARDI S., SALMASO B., LACOGNATA C., BATTAGLIN F., CAVALLIN F. *et al.* Angiogenesis inhibitors and symptomatic anal ulcers in metastatic colorectal cancer patients. *Acta Oncol*, 2018, **57** : 412-9.
58. GROSSI A.E.L.M., RODRIGUEZ J.E.R., DE FREITAS SOUSA A.A., MACHADO D.A.B., DE ALBUQUERQUE V.V.M.L., DE MACEDO F.P.P.C. Management of unusual rectal foreign body - Case report and literature review. *Int J Surg Case Rep.*, 2022, **94** : 107051.
59. COSKUN A., ERKAN N., YAKAN S., YILDIRIM M., CENGIZ F. Management of rectal foreign bodies. *World J Emerg Surg.*, 2013, **8** : 11.
60. CINAR H., BERKESOGU M., DEREBEY M., KARADENIZ E., YILDIRIM C., KARABULUT K. *et al.* Surgical management of anorectal foreign bodies. *Niger J Clin Pract.*, 2018, **21** : 721-5.
61. SENÉJOUX A. Sexualité anale : des réponses médicales aux questions des patients. *Journées Francophones D'hépatogastroentérologie Et D'oncologie Digestive (JFHOD)*. Paris, 2020.
62. NZIMBALA M.J., BRUYNINX L., PANS A., MARTIN P., HERMAN F. Chronic anal fissure: common aetiopathogenesis, with special attention to sexual abuse. *Acta Chir Belg.*, 2009, **109** : 720-6.

63. BANG G.A., TOLEFAC P., SAVOM E.P., BWELLE MOTO G., SOSSO M.A. Anal/anogenital lesion revealing child sexual abuse: A case series of an unusual situation in a black African setting. *Int J Surg Case Rep.*, 2020, **76** : 341-4.
64. CLIFFORD G.M., GEORGES D., SHIELS M.S., ENGELS E.A., ALBUQUERQUE A., POYNTEN I.M. *et al.* A meta-analysis of anal cancer incidence by risk group: Toward a unified anal cancer risk scale. *Int J Cancer.*, 2021, **148** : 38-47.
65. PALEFSKY J.M., LEE J.Y., JAY N., GOLDSTONE S.E., DARRAGH T.M., DUNLEVY H.A. *et al.* Treatment of Anal High-Grade Squamous Intraepithelial Lesions to Prevent Anal Cancer. *N Engl J Med.*, 2022, **386** : 2273-82.
66. NORDENVALL C., NYRÉN O., YE W. Elevated anal squamous cell carcinoma risk associated with benign inflammatory anal lesions. *Gut*, 2006, **55** : 703-7.
67. CHAE W., KANG S.Y., JANG S.I., HAN Y.D. Risk of Anorectal Cancer Associated with Benign Anal Inflammatory Diseases: A Retrospective Matched Cohort Study. *Int J Environ Res Public Health*, 2022, **19** : 7467.
68. BARBEIRO S., ATALAIA-MARTINS C., MARCOS P., GONÇALVES C., COTRIM I., VASCONCELOS H. A Case Series of Anal Carcinoma Misdiagnosed as Idiopathic Chronic Anal Fissure. *GE Port J Gastroenterol.*, 2017, **24** : 227-31.
69. MARRES C.C., DRILLENBURG P., VERBEEK P.C. [Patients with a therapy-resistant anal fissure: beware of malignancies]. *Ned Tijdschr Geneesk.*, 2014, **158** : A7646.
70. GAUR K., PURI V., JAIN M., HOODA S., SHARMA S., ANDLEY M. Acute myeloid leukemia presenting as fissure-in-ano: A unique case of histologically proven anodermal leukemia cutis. *Indian J Pathol Microbiol.*, 2019, **62** : 645-6.