

## Olmesartan induced weight loss and small vessel vasculitis

E. Vanbelleghem<sup>1</sup>, T. Taelman<sup>2</sup>, J. Werbrouck<sup>3</sup>, L. Libbrecht<sup>4</sup>, F. D'Heygere<sup>5</sup>

(1) Department of Clinical Genetics, University Gent; (2) Department of Internal Medicine, University Leuven; (3) Department of Dermatology, Kortrijk; (4) Department of Pathological Anatomy, AZ Groeninge Kortrijk; (5) Department of Internal Medicine and Gastro-enterology, AZ Groeninge Kortrijk.

### Abstract

This case report describes a 52-year-old male patient with important weight loss, fatigue, diarrhea and a skin eruption since 1 year. Olmesartan-induced enteropathy and skin vasculitis were diagnosed. The onset of symptoms occurred almost two years after the initiation of the angiotensin receptor blocker therapy. There was a total resolution of the symptoms after the cessation of olmesartan. Although sprue-like enteropathy and cutaneous vasculitis are very rare, clinicians should be aware of those potential adverse events, even years after the initiation of an angiotensin II receptor blocker. (*Acta gastroenterol. belg.*, 2023, 86, 102-104).

### Introduction

Olmesartan-induced enteropathy was first described in 2012 by Rubio-Tapia et al. and is characterized by chronic diarrhea and weight loss that does not improve with a gluten-free diet (1). Since then, several similar cases have been reported. In addition to weight loss and chronic diarrhea, fatigue, nausea, vomiting, abdominal pain, cramps and bloating have also been reported. Typically, these are patients with villus atrophy and elevated intraepithelial lymphocytes on a duodenal biopsy, with no detectable anti-tissue transglutaminase type IgA antibodies (anti-tTG-IgA) and no response to a strict gluten-free diet (1-6). To the best of our knowledge, this is the first case in which both an enteropathy and a clinical picture suggestive of small-vessel cutaneous vasculitis could be detected while taking an angiotensin II receptor blocker (ARB). The literature describes several cases of skin vasculitis with other ARBs, but not yet after the use of olmesartan.

### Clinical history

A 52-year-old man presented at the outpatient clinic after being referred by his general practitioner because of weight loss, fatigue and diarrhea.

The patient had lost 17 kg (from 104 to 87 kg) in 16 months, initially thought to be due to increased daily activity. Despite this weight loss, the patient felt an abnormal and increasing fatigue, falling asleep every evening in front of the television. Other symptoms included loss of energy and cold intolerance. In addition, his stool consistency had changed somewhat, being softer and floating in the toilet, smelling more than before. Stool frequency however remained unaltered at three times daily. His appetite did not change either.

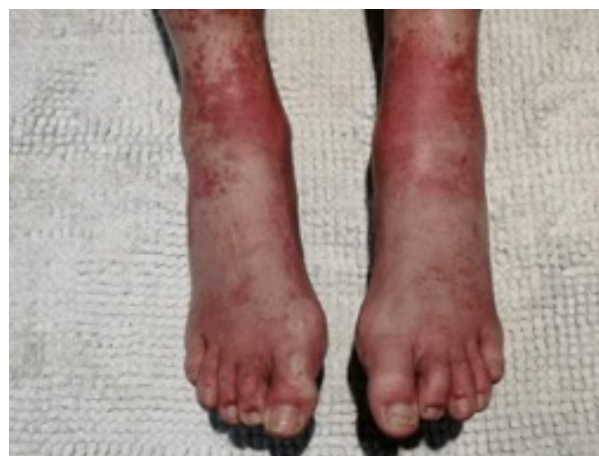

Figure 1. — Purpuric eruptions on the lower extremities suggestive for small-vessel vasculitis.

He also experienced 6 episodes of a purpuric rash in the lower extremities in the past 10 months. These were accompanied by a burning sensation in both calves. The first episode dragged on for 4 weeks. Subsequent episodes lasted 5 to 10 days. The lesions had already disappeared when the patient presented himself to the dermatologist, hence biopsies could not be taken. Clinical photographs (figure 1.) showing the lesions were very suggestive for small-vessel cutaneous vasculitis. A treatment with a nonsteroidal anti-inflammatory drug and topical steroid ointment was instituted. Symptom-free intervals of 5 to 8 weeks were obtained. During flare-ups, blood samples were taken repeatedly, without inflammatory abnormalities. The diagnosis of an underlying systemic vasculitis was also considered, but no proteinuria, nor hematuria were present. C3c and C4 were normal, Cryoglobulins were negative. The antineutrophil cytoplasmic antibodies (ANCA) and the antinuclear antibody (ANF) were positive with titers of 1/160 and 1/640 respectively. The ANCA were labeled as atypical on two occasions, with a negative proteinase 3 (PR3) and a negative myeloperoxidase (MPO).

Correspondence to: Dr. F. D'Heygere, Department of Internal Medicine and Gastroenterology, AZ Groeninge, President JF Kennedylaan 4, 8500 Kortrijk, Belgium.

Email: francois.dheygere@azgroeninge.be

Submission date: 12/03/2022

Acceptance date: 28/03/2022

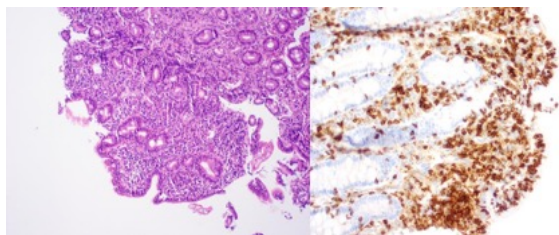


Figure 2. — A: hematoxyline-eosine stain with 100 times magnification shows nearly total duodenal villus atrophy; B: Increased duodenal intra-epithelial T-lymphocytes on this CD3-stain with magnification times 200.

The ANF, on the other hand, was clearly positive (roughly speckled) with antibodies against nuclear ribonucleoprotein (nRNP), nucleosomes and Smith (Sm) in further detail.

His medical history included arterial hypertension, for which the patient took olmesartan 40 mg once daily. This was started 31 months before presenting at the outpatient clinic, 21 months before the onset of the weight loss and fatigue and 15 months before the onset of purpura. In the family history we noticed that his mother died of colon cancer at the age of 46.

Clinical examination showed normal cardiac and lung auscultation, patient was afebrile with a blood pressure of 110/72 mmHg. The patient's BMI was 23.1 kg/m<sup>2</sup>. The abdomen was tender, palpable glands appeared absent, some mild residual petechial lesions were noted on the lower limbs.

Biochemistry was non-inflammatory with a normal number of red blood cells, white blood cells and platelets. The highlights were mildly increased transaminases (aspartate aminotransferase: 47 U/l (ref. 0-43 U/l), ALT: 66 U/l (ref. < 60 U/l)), as well as a decreased vitamin B12 (172 ng/l ((ref. > 200 ng/l)). There was no folic acid deficiency (4.10 µg/l (ref. > 3.88 µg/l)). Hepatitis B and C serology were negative.

Urine and faeces samples (including Sudan staining for fat) were negative. Steatorrhea could thus not be confirmed. An ultrasound of the abdomen showed no abnormalities in addition to an edge-high value of the spleen size (13.6 cm). A colonoscopy was performed in view of the family history of colon carcinoma and the altered bowel pattern of the patient. This showed a normal aspect of the different colon segments. The biopsies taken were also normal. In view of the low vitamin B12 value, a gastroduodenoscopy was performed, revealing a normal macroscopic aspect of the esophagus, stomach, bulb and duodenum. However, duodenal biopsies showed almost complete villus atrophy with an increased number of intraepithelial T lymphocytes (Figures 2A-B) suggesting gluten enteropathy. The complaints of fatigue, reduced vitamin B12 content supported this suspicion. However, tTG-IgA antibodies were determined and were not elevated.

Given the villus atrophy in this patient, with negative anti-tTg-IgA, a tentative diagnosis of an olmesartan-

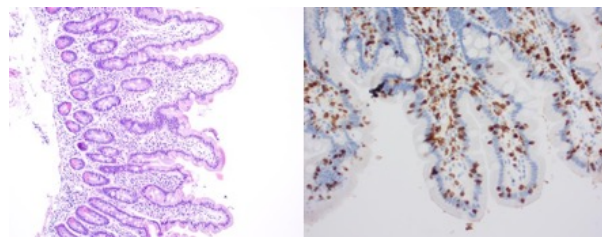


Figure 3. — A: Complete recovery of the duodenal villi. This concerns a hematoxylin-eosin staining with a magnification of 100x; B: Normalization of the number of intraepithelial T lymphocytes. This is a CD3 staining with a magnification of 200x.

induced enteropathy was made. Although celiac disease could not be completely ruled out in this case, it was decided to stop olmesartan first without initiating an additional gluten-free diet. Olmesartan 40 mg was discontinued and replaced by amlodipine 10 mg. The patient received oral vitamin B12 supplementation. A very swift improvement in his general condition and feeling of well-being occurred. The patient returned to the outpatient clinic after 8 weeks in complete remission. He had no longer experienced any symptoms of fatigue nor diarrhea. The attacks of generalized itching and skin vasculitis in the lower extremities did not reoccur. He had regained 4 kg during this period. Control biopsies 8 weeks after cessation of Olmesartan showed complete recovery of the duodenal villi with a normalization of the number of intraepithelial lymphocytes (Figures 3A-B). The elevated transaminases also normalized after discontinuation of olmesartan.

Twelve months after stopping the angiotensin II receptor blocker (ARB) the patient's general practitioner reported a sustained remission and no recurrence of vasculitis.

## Discussion

Olmesartan-induced enteropathy is a relative novel entity being first described by Rubio – Tapia et al. in 2012 (1). It is characterized by chronic diarrhea and weight loss, accompanied by suggestive duodenal biopsies with villus atrophy and elevated intraepithelial lymphocytosis, that does not improve with a gluten-free diet and have negative tTG-IgA antibodies (1-6). In addition to duodenal villus atrophy, microscopic colitis and/or lymphocytic/collagenous gastritis has also been described (1,2,7). The time between exposure to olmesartan and the onset of symptoms is highly variable, lasting an average of 3.1 years (1). The exact mechanism of this intestinal damage is still unknown (1, 3-6). The long time between exposure and symptoms is rather suggestive of a cell-mediated immune response (1).

Biochemically, the following can be seen in an olmesartan-induced enteropathy: a normochromic normocytic anemia, leukopenia, hypoalbuminemia, vitamin deficiencies and electrolyte disturbances (1-5). In this

case, an increased AST and ALT were also found, which has already been described in two other case reports. There was a concomitant rise in transaminases that, as in this case, normalized after discontinuation of olmesartan (5, 8).

The patient in this case also had a recurrent skin eruption in the lower extremities. Although no biopsy could be taken, the clinical picture was typical for a small-vessel cutaneous vasculitis (Fig. 1). Data on angiotensin receptor blockers (ARB)-induced skin eruptions are scarce in the literature. In 2015, a picture of urticarial vasculitis after taking telmisartan was described (9). In addition, there were also cases of vasculitis after the use of losartan, with IgA and IgG depositions on the biopsies (10,11). A case of both lymphocytic vasculitis of the skin and renal involvement with a nephrotic syndrome has also been described for candesartan (12). This rare side effect of vasculitis thus appears to be a class-related phenomenon. In addition to vasculitis, multiple cases of maculopapular eruptions have been reported due to ARBs (13,14). Although described predominantly after the intake of olmesartan, a recent systematic review also found an ARB-induced enteropathy after the use of valsartan, losartan, candesartan, irbesartan and telmisartan, suggesting that this rare side effect is indeed class-related (15).

When a diagnosis of ARB-induced enteropathy or vasculitis is suspected, the medication should be discontinued (1-5, 9). An improvement in the symptoms of the enteropathy is to be expected in the following days. However, the speed and extent of recovery varies. Literature reports complete recovery of the mucosa after an average of 3 to 6 months (2). In addition, the nutritional status caused by the malabsorption should normalize (2,3,5). Even cases which required hospitalization for intravenous rehydration have been described (1,3). In a few cases, the patient's condition was so precarious that the initiation of total parenteral nutrition appeared necessary (1,3,4). In selected cases (severe clinical presentations, recurrent hospitalizations and slow or partial response after discontinuation of olmesartan) temporary administration of budesonide or intravenous steroids is warranted (1,2,4).

## Conclusion

This patient with symptoms of weight loss, pronounced fatigue, diarrhea, and recurrent vasculitis lesions of the lower extremities for 1.5 years showed duodenal villus atrophy with undetectable tTG-IgA antibodies. The diagnosis of an olmesartan-induced enteropathy with a clinical diagnosis suggestive of small-vessel cutaneous vasculitis was made. The patient had been taking olmesartan for a long time in the context of arterial hypertension. Stopping this ARB and replacing it with amlodipine was followed by a very swift subjective improvement accompanied with a regain of weight of 4 kg in 8 weeks and the complete absence of the recurrent

skin eruption. After 8 weeks, control biopsies showed complete recovery of the duodenal villi.

To the best of our knowledge, this is the first case in which both an enteropathy and a clinical picture suggestive of small-vessel cutaneous vasculitis could be detected while taking an ARB. The literature describes several cases of skin vasculitis with other ARBs, but not yet after the use of olmesartan. Although olmesartan is most commonly associated with enteropathy, it appears that this side effect, like that of skin vasculitis, is also seen in other ARBs. Although such ARB-induced enteropathy and vasculitis are very rare, clinicians should remain vigilant for these side effects, which may not occur even after years of ARB use.

## Conflict of interest

No conflict of interest of financial aid to declare.

## References

- RUBIO-TAPIA A., HERMAN ML., LUDVIGSSON JF., KELLY DG., MANGAN TF., Wu TT., et al. Severe spruelike enteropathy associated with olmesartan. *Mayo Clin Proc.*, 2012, **87**(8):732-738.
- HUJOEL IA., RUBIO-TAPIA A., Sprue-like enteropathy associated with olmesartan: a new kid on the enteropathy block. *GE Port J Gastroenterol.*, 2016, **23**: 61-65.
- CHOI EY., McKENNA BJ. Olmesartan-associated enteropathy: a review of clinical and histologic findings. *Arch Pathol Lab Med.*, 2015, **139**: 1242-1247.
- KEMPENAERS S., BOGAERT J., DE MAEYER M., VAN HAUTHEM P., RAMAEL M., SCHOETERS P., Olmesartan-induced enteropathy treated with budesonide. *Acta Gastroenterol Belg.*, 2019, **82**(2):319-321.
- EUSEBIO M., CALDEIRA P., ANTUNES AG., ROMAS A., VELASCO F., CADILLA J., et al. Olmesartan-induced enteropathy: an unusual cause of villous atrophy. *GE Port J Gastroenterol.*, 2016, **23**: 91-95.
- DONG YH., JIN Y., TSACOGIANIS TN., HE M., HSIEH PH., GAGNE JJ. Use of olmesartan and enteropathy outcomes: a multi-database study. *Aliment Pharmacol Ther.*, 2018, **47**: 792-800.
- SHENBAGARAJ L., SWIFT G., Olmesartan-associated severe gastritis and enteropathy. *BMJ Case Rep.*, 2018, **11**: e226133.
- KOGACHI S., TREYZON L., Waters K., Sundaram V., Liver injury related to olmesartan-associated sprue-like enteropathy. *Liver Int.*, 2019, **39**: 2204.
- MAHAJAN VK., Singh R., Gupta M., Raina R.,nTelmisartan induced urticarial vasculitis. *Indian J Pharmacol.*, 2015, **47**: 560-562.
- PIERARD FRANCHIMONT C., HENRY F., PIERARD GE., Severe pustular and polymorphous vasculitis caused by losartan. *Ann Dermatol Venereol.*, 2001, **128**: 1040-1042.
- SHALAVADI MH., MANGANAVAR CV., MEDEPALLI P., Losartan induced vasculitis and anaemia: a case report in tertiary care hospital. *Ind J Pharm Pract.*, 2015, **8**: 197.
- MORTON A., MUIR J., LIM D., Rash and acute nephritic syndrome due to candesartan. *BMJ.*, 2004, **328**: 25.
- CARDOSO BK., MARTINS M., FARINHA SM., VISEU R., TOMAZ E., INACIO F., Late-onset rash from irbesartan: an immunological reaction. *Eur J Case Rep Intern Med.*, 2019, **6**: 001128.
- BHUSHAN A., VED BHUSHAN ST., Olmesartan: induced maculopapular rash. *Indian J Pharmacol.*, 2013, **45**: 199-200.
- KAMAL A., FAIN C., PARK A.,WANG P., GONZALEZ-VELEZ E., A LEFFLER D., et al. Angiotensin II receptor blockers and gastrointestinal adverse events of resembling sprue-like enteropathy: a systematic review. *Gastroenterol Rep.*, 2019, **7**: 162-167.