

A 43-year-old male with acute right upper quadrant pain and skin rash

F. Ufuk, A.R. Utebey, S. Yilmaz

Pamukkale university, School of Medicine, Pamukkale, Denizli, Turkey.

Question

A 43-year-old male presented with acute right upper quadrant pain, nausea, and itchy skin rash for two hours. Physical examination revealed abdominal tenderness and itchy abdominal skin lesions that are compatible with urticaria. The patient's blood pressure was 95/55 mmHg, pulse rate was 122 beats/minute, body temperature was 37.1 C degrees, and partial oxygen saturation was 96% in the room air. He had no history of recent trauma or chronic disease. Laboratory test results were within normal limits except for increased white blood cell count (14.79 K/uL, reference range; 4-10 K/uL). Abdominal ultrasound (US) was performed, and the US revealed abdominal free fluid and a thin-walled lobulated cystic lesion in the liver dome. For further evaluation, contrast-enhanced abdominal computed tomography (CT) was obtained. CT showed a thin-walled cystic lesion with lobulated contours in the liver, pericystic fat stranding, perihepatic free fluid, and right pleural effusion (Figure 1).

What is the diagnosis?

cystic lesion rupture. Hydatid cyst, simple hepatic cyst, cystic metastasis, and mucinous cystic neoplasm of the liver (MCN-L) can be considered in the differential diagnosis of hepatic cystic lesions that may rupture. When imaging features evaluated with clinical findings, hydatid cyst rupture was considered at the forefront in the presence of urticarial lesions. Acute symptoms were treated with intravenous methylprednisolone, epinephrine, and pheniramine maleate. The indirect hemagglutination test was positive at 1/640 titer for hydatid cyst, and oral albendazole therapy (800 mg/day) was started. Then, image-guided percutaneous treatment was performed for the hydatid cyst. One-year follow-up of the patient was uneventful.

Hydatid cyst (HC) is caused by *Echinococcus* species and has a 5-10% prevalence in endemic areas (1). The liver is the most involved organ, mainly the right hepatic lobe. The cyst growth rate is variable, and cysts are rarely symptomatic until they reach approximately 8-10 cm in diameter (1,2). However, patients can present complications due to cyst rupture and biliary obstruction (2,3). Estimates of spontaneous rupture of HC rates

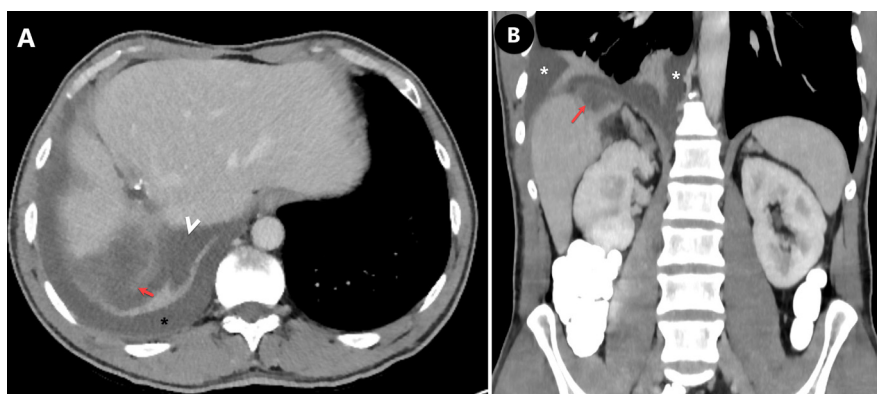


Figure 1. — Recently obtained, **A)** axial and **B)** coronal contrast-enhanced abdominal computed tomography (CT) images show a thin-walled cystic lesion with lobulated contours in the liver dome (red arrows), pericystic fat stranding, perihepatic free fluid (arrowhead), and right pleural effusion (*).

Answer

Abdominal CT showed a thin-walled cystic lesion with lobulated contours in the liver dome, pericystic fat stranding, perihepatic free fluid, and right pleural effusion. CT findings suggest the diagnosis of hepatic

Correspondence to: Furkan Ufuk, Pamukkale university, School of Medicine, Pamukkale, Denizli, 20070 Turkey.
Email: furkan.ufuk@hotmail.com

Submission date: 21/06/2021
Acceptance date: 26/07/2022

vary according to different series, and it can cause complications such as abdominal pain, nausea, vomiting, and anaphylaxis (3). Anaphylaxis is an emergency condition and can result in death. Therefore, in patients with sudden abdominal pain and skin rash, hydatid cyst rupture should be kept in mind.

References

1. ECKERT J, DEPLAZES P. Biological, epidemiological, and clinical aspects of echinococcosis, a zoonosis of increasing concern. *Clin Microbiol Rev.* 2004;**17**(1):107-35.
2. UFUK F, DURAN M. Intrabiliary Rupture of Hepatic Hydatid Cyst Leading to Biliary Obstruction, Cholangitis, and Septicemia. *J Emerg Med.* 2018;**54**(1):e15-e17.
3. BEN JOMAA S, HAJ SALEM N, HMILA I, et al. Sudden death and hydatid cyst: A medicolegal study. *Leg Med (Tokyo).* 2019;**40**:17-21.